Pediatric Oral Health

Smiles for Tomorrow

Topics

- Normal Oral Structures

- Common Oral Conditions

- Eruption Patterns

- Dental Caries and Prevention

- Orofacial Trauma

Advisory Panel

- Content development and photography

  Steven M. Adair, DDS, MS

  Priscilla Johns Bond, DMD

  Robert Jon Feigal, DDS, PhD

  Constance M. Killian, DMD

  Joan C. Linhardt, MD, FAAP

  Gail E. Molinari, DDS, MS

  Arthur J. Nowak, DMD

  James F. Steiner, DDS

Advisory Panel

- Additional photographs were contributed by:

  Timothy Kosinski, MS, DDS

  Luc C. Martens, DDS

  Donna Napiorkowski, RDH

  Keith L. Ray, DMD

  Deirdre R. Sams, DDS

  O.B. Sveen, DDS

Normal Oral Structures

- Frenum
- Buccal Mucosa
- Tongue
- Gingiva
- Alveolar Mucosa
- Masticatory Mucosa
- Palate
- Tooth Form

Normal Oral Structures

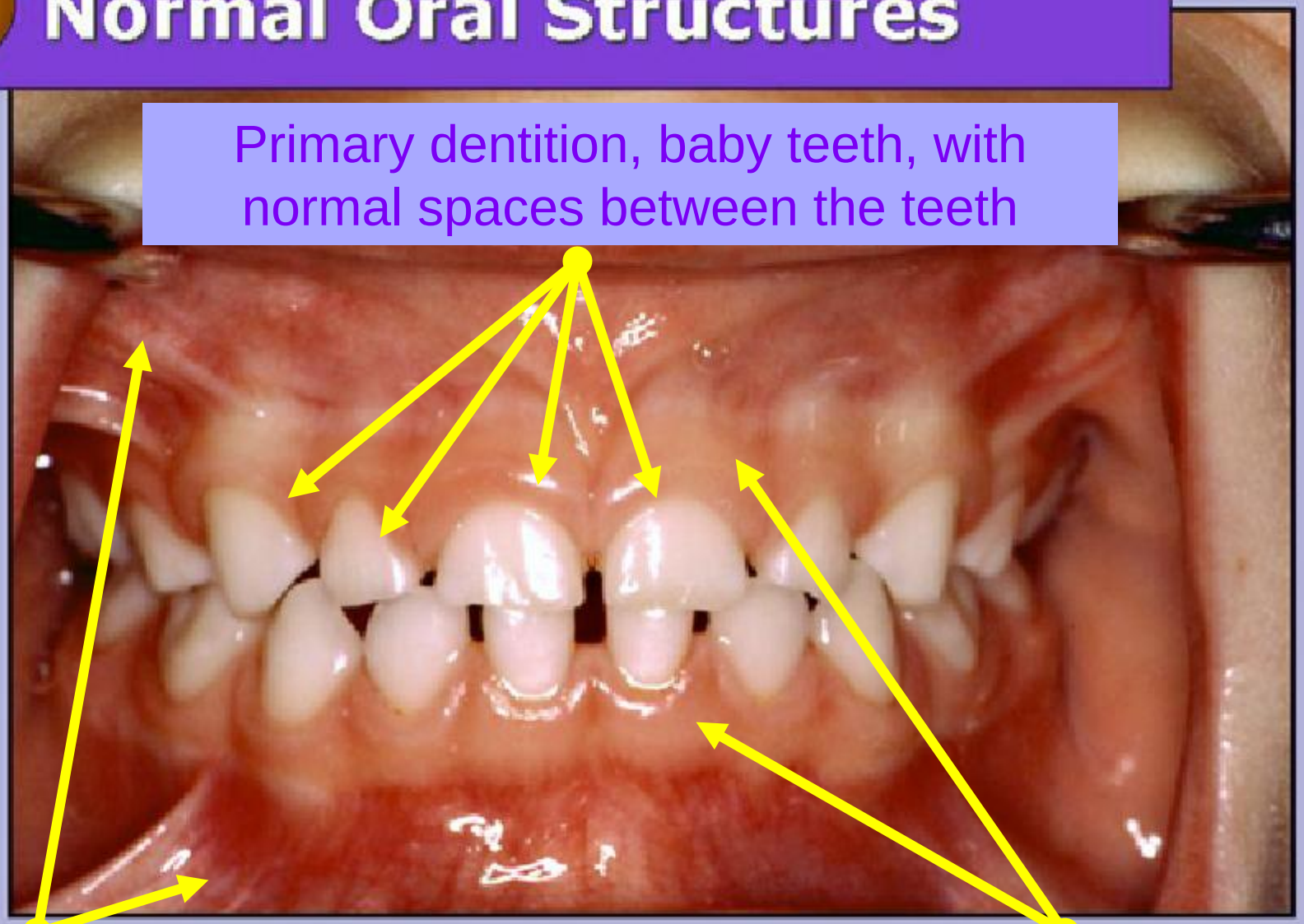

Primary dentition, baby teeth, with normal spaces between the teeth

Mucosa

Gingiva

Normal Frenum

The labial frenum is fibrous tissue between the the lip and the mucous membrane above the gum tissue.

Diastema in a Six-year-old

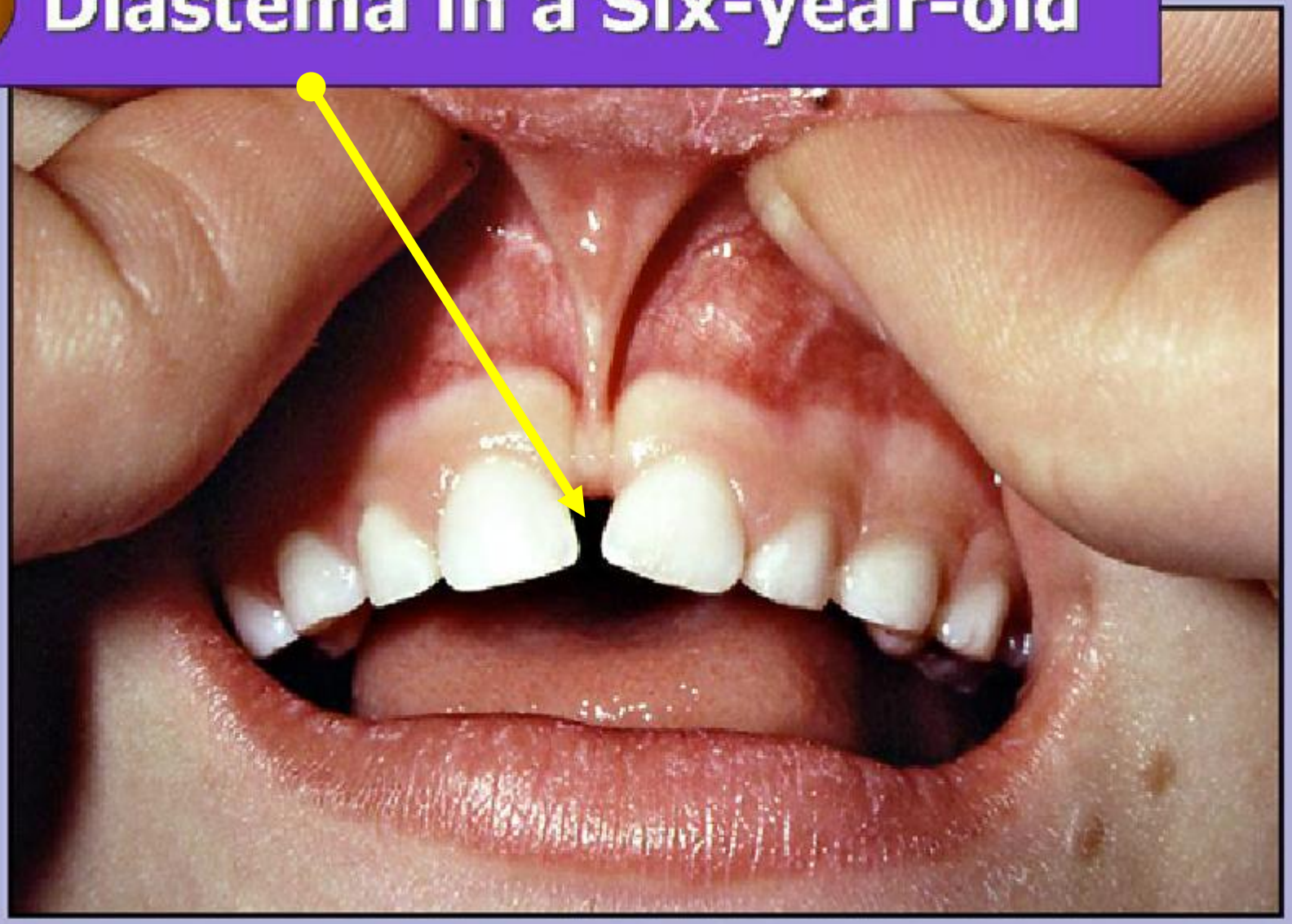

A diastema is a space between teeth.

Diastema in an Eight-month-old

The "Ugly Duckling" Stage

The "ugly duckling" stage is often mistaken by parents as an orthodontic problem because there is a space between the top central incisors. This may be the norm between ages 7 through 12 years of age, and usually is not connected with a permanent space between the teeth. In this stage baby teeth are being lost and permanent teeth have not completely erupted.

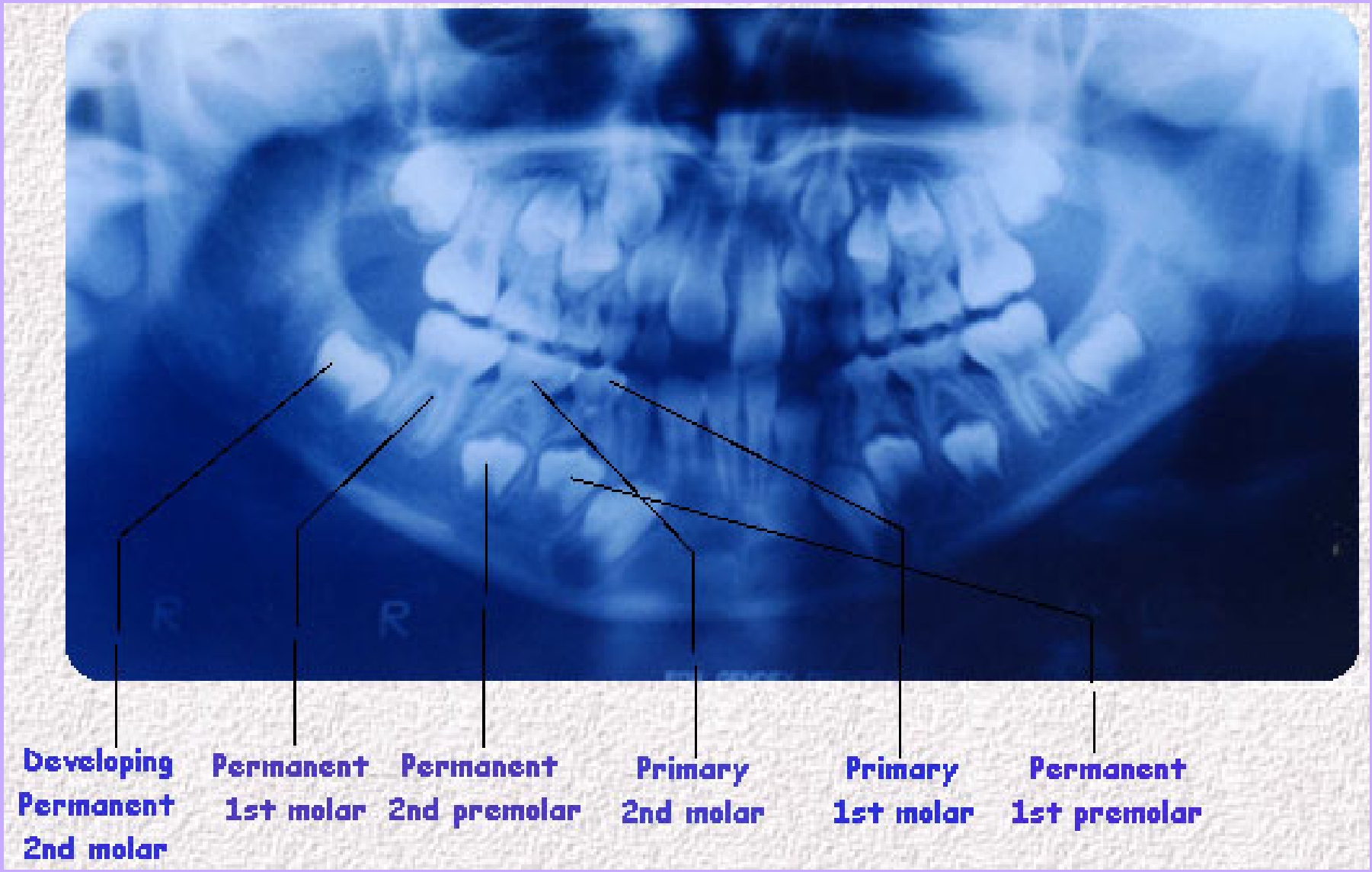

A panoramic x-ray of a 7 year-old child. One can notice the complex mix of the permanent and the primary teeth at this stage.

Buccal Mucosa

The soft tissue lining the inside of the cheek.

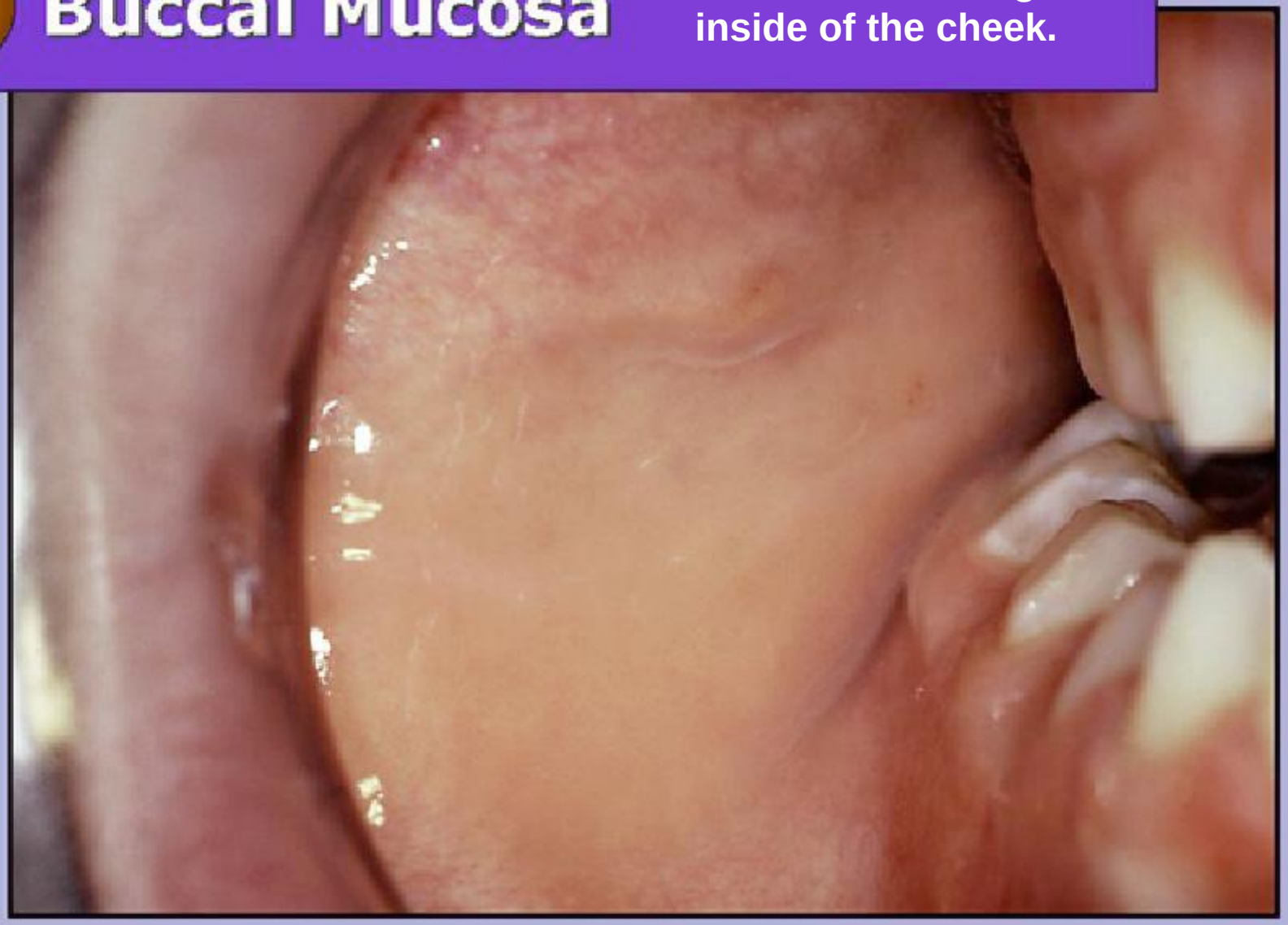

Trauma from Cheek Biting

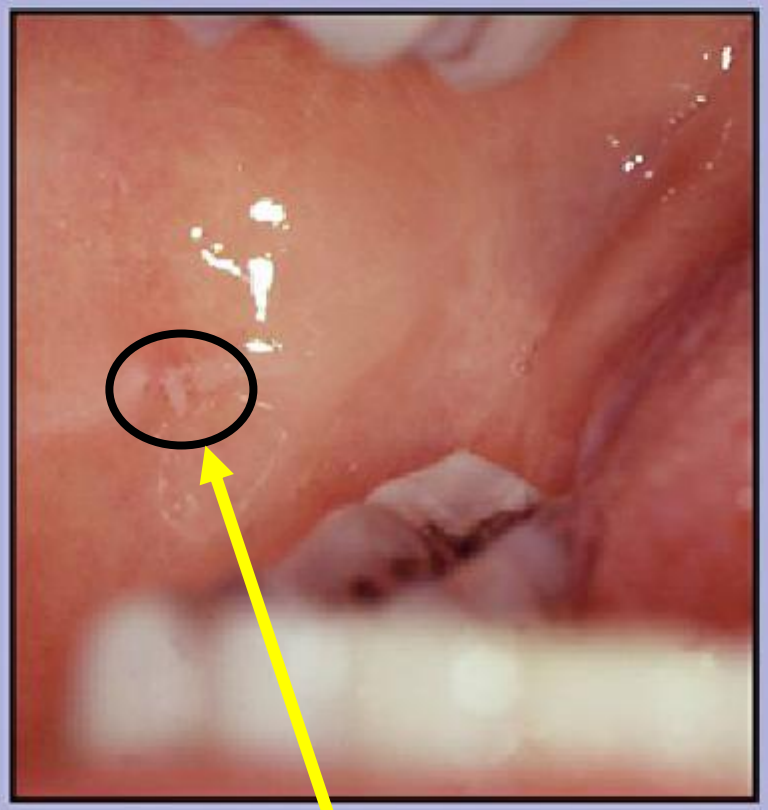

Cheek Bite

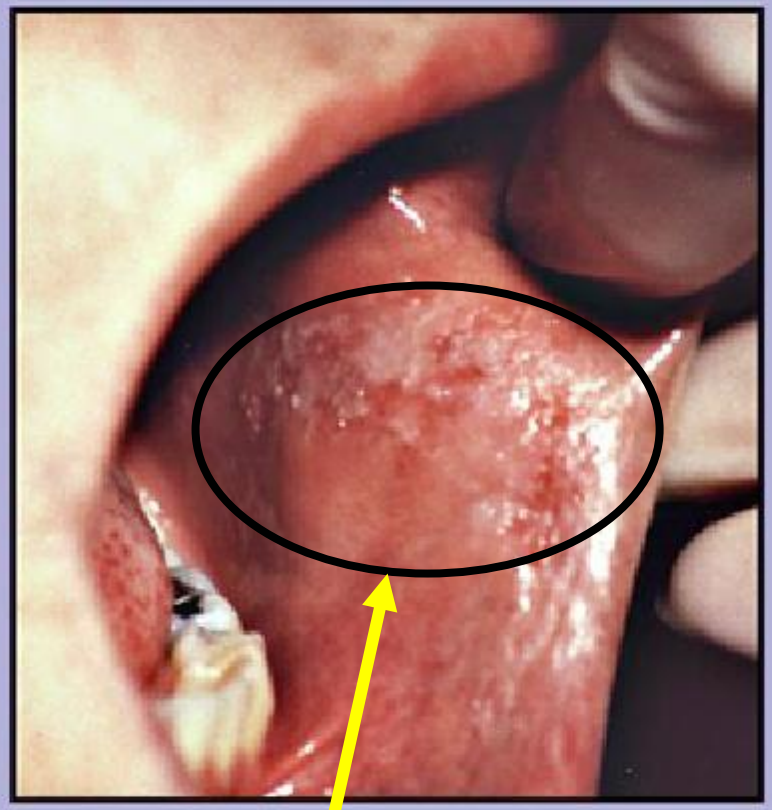

Chronic cheek biting

Tongue: Ventral Surface

(the underside of the tongue)

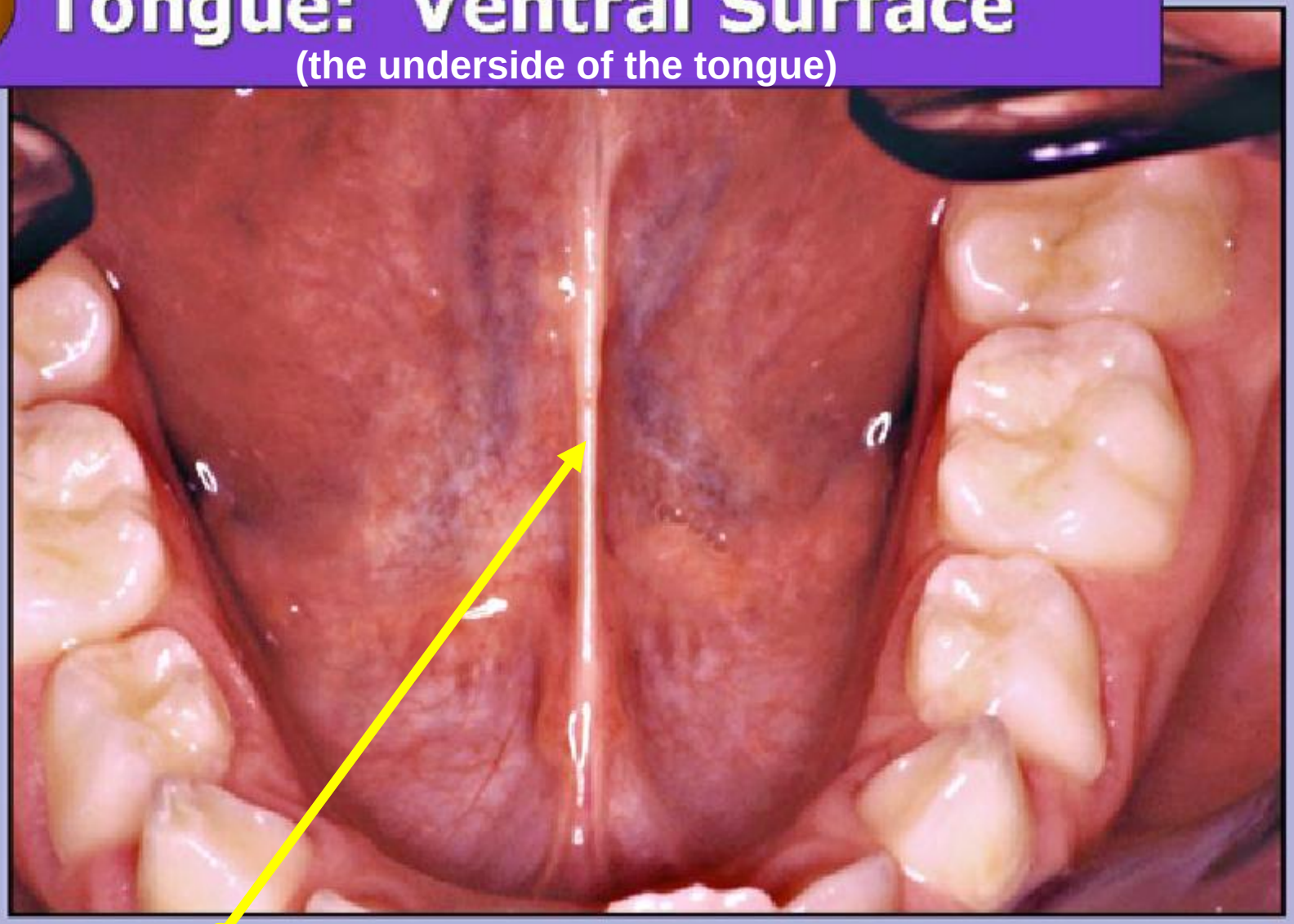

Lingual frenum

Tongue: Dorsal Surface

(the top side of the tongue)

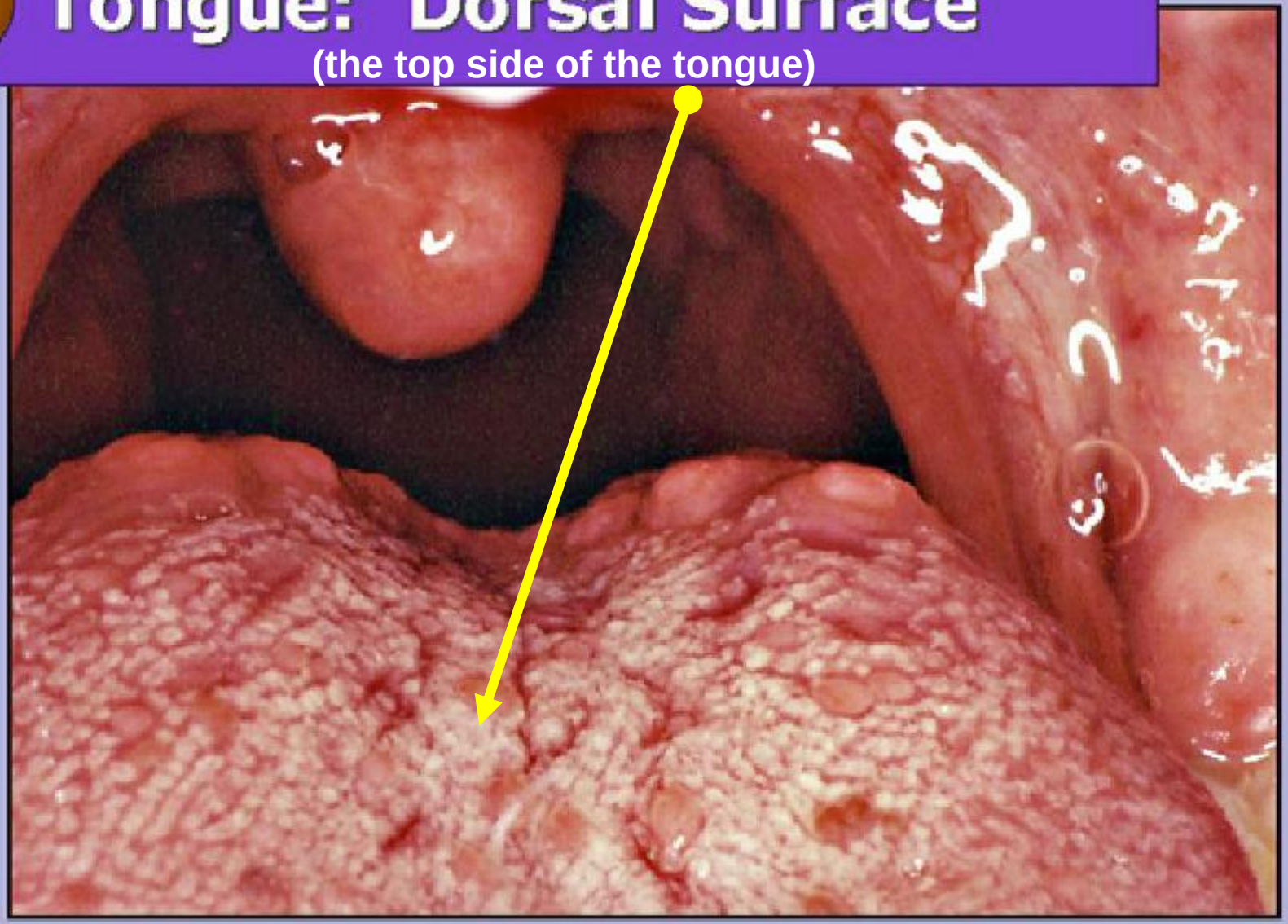

Gingiva (Gums)

Healthy gingiva, gum tissue, is coral pink in color and has a stippled or orange peel surface texture.

Pigmented Pediatric Gingiva

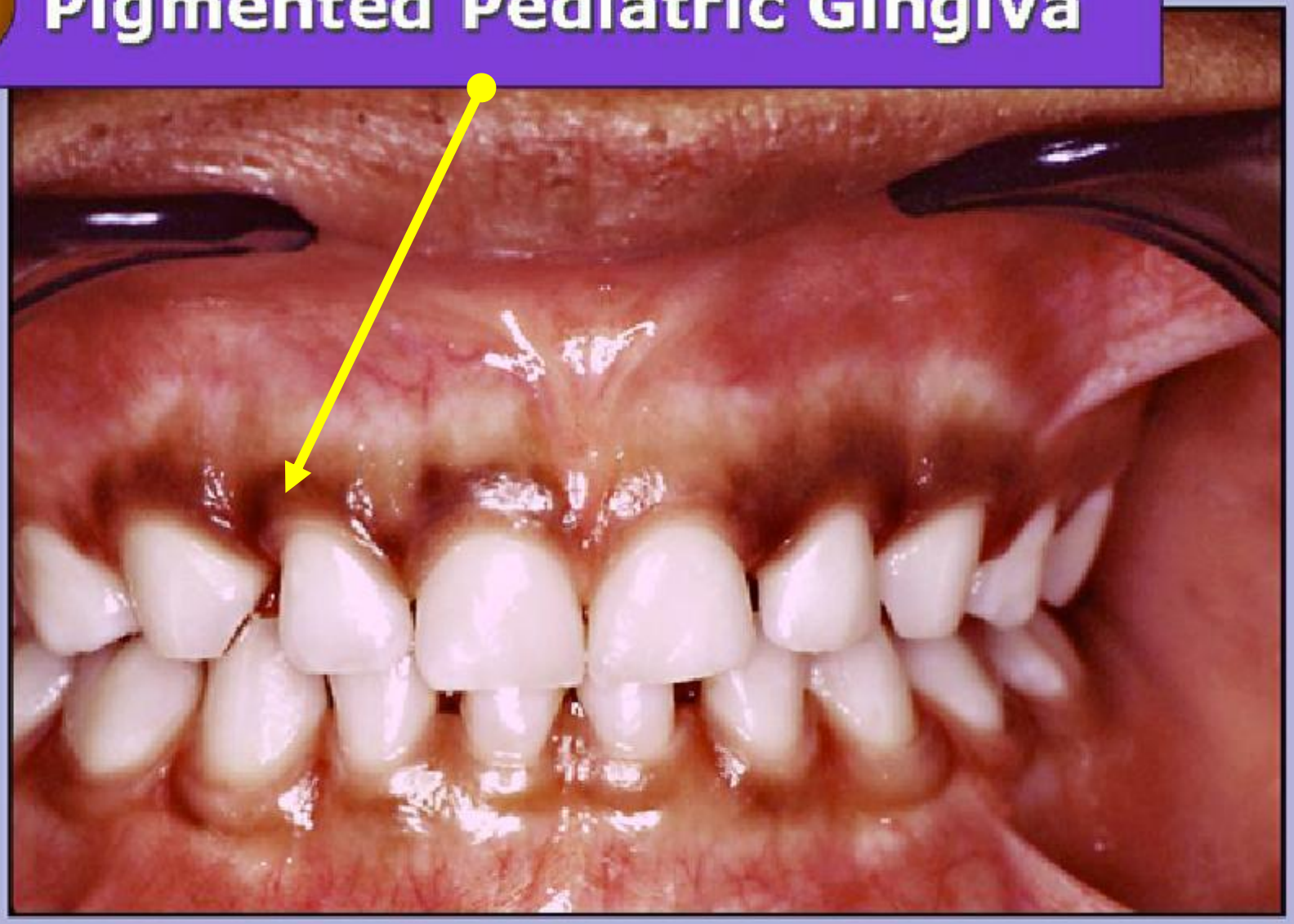

Pigmentation in the gum tissue is normal in African Americans.

Normal Hard Palate

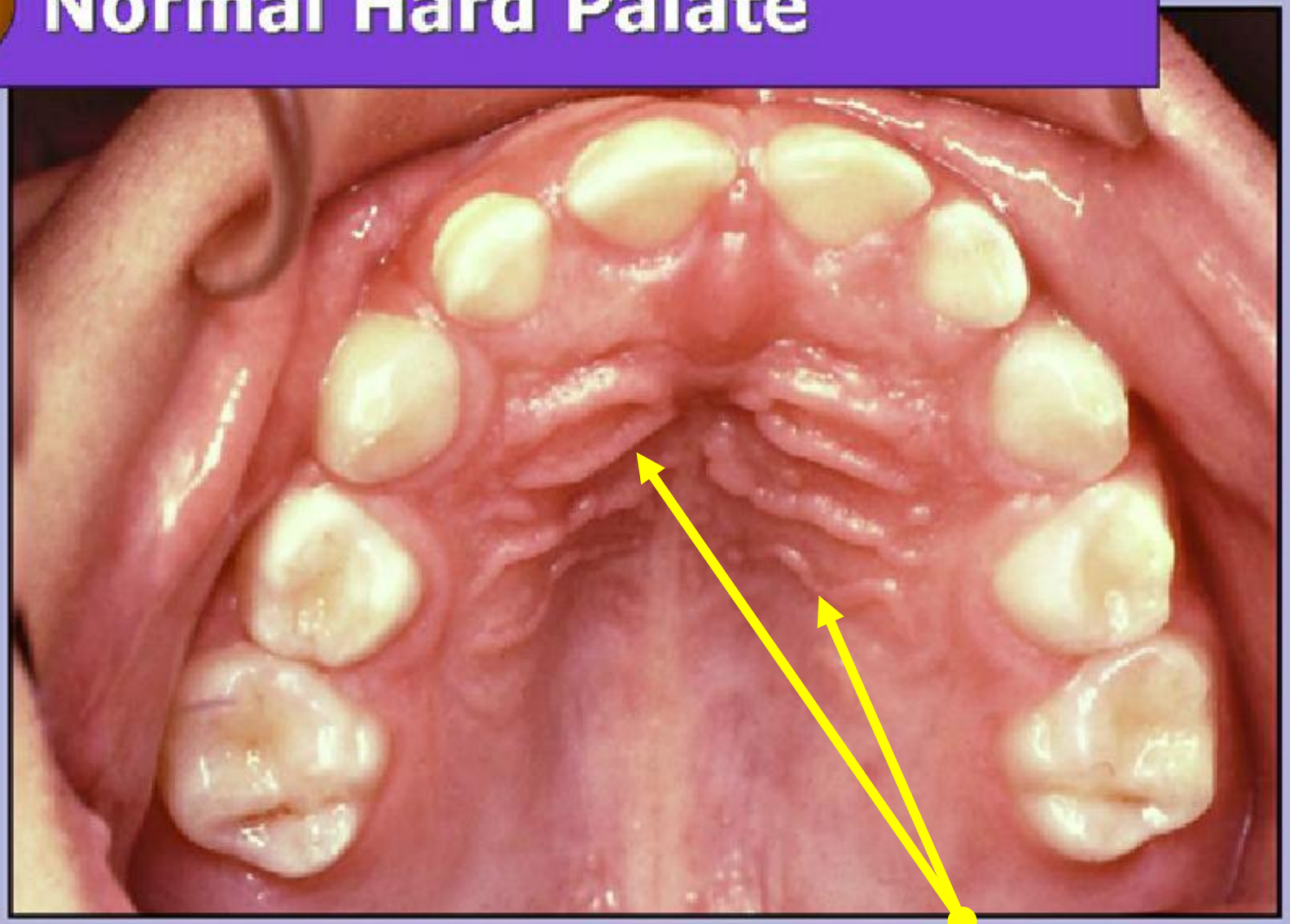

The front part of the hard palate is covered by irregular ridges

Junction of the Hard and Soft Palate

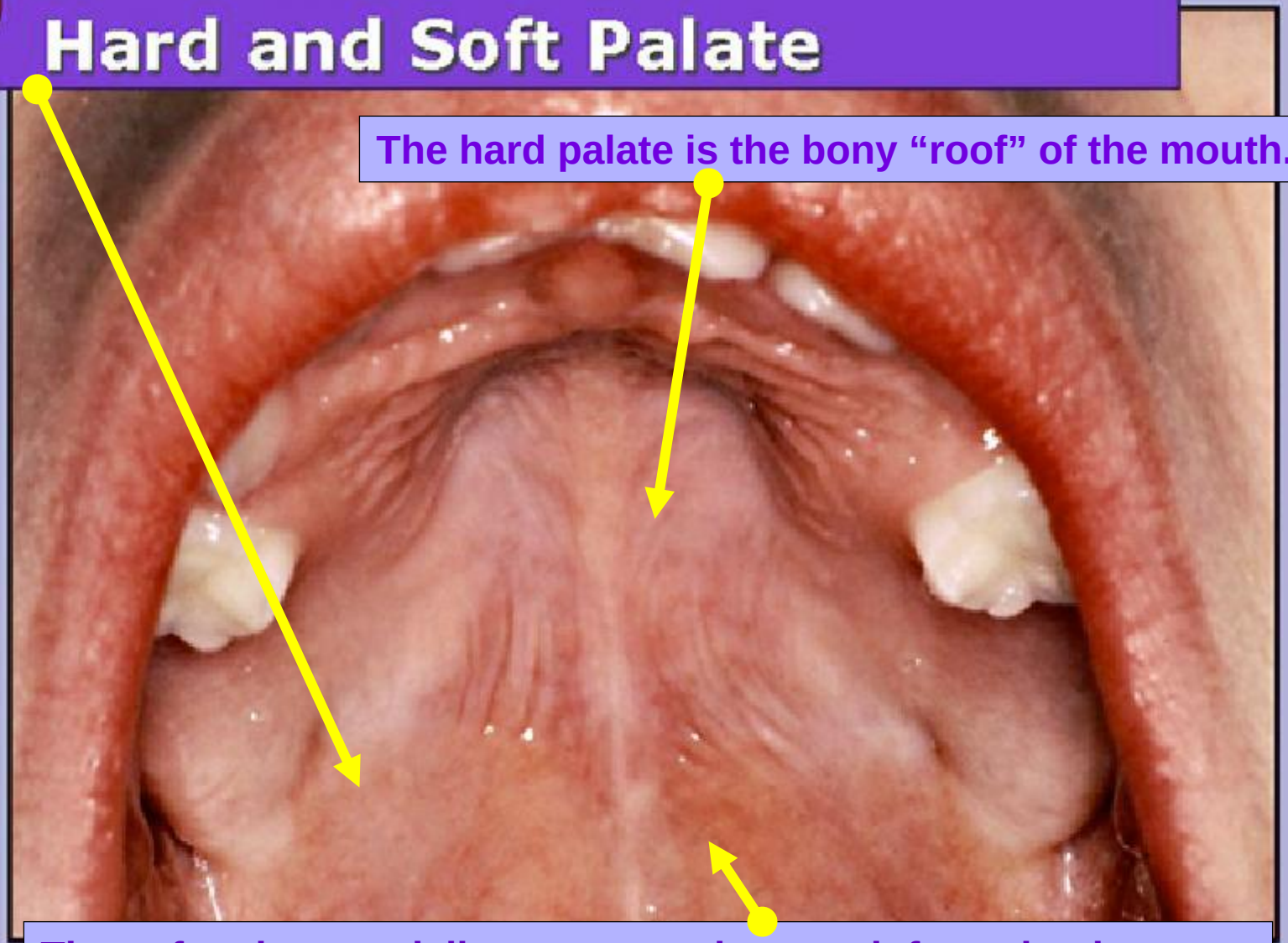

The hard palate is the bony “roof” of the mouth.

The soft palate partially separates the mouth from the throat

Soft Palate and Uvula

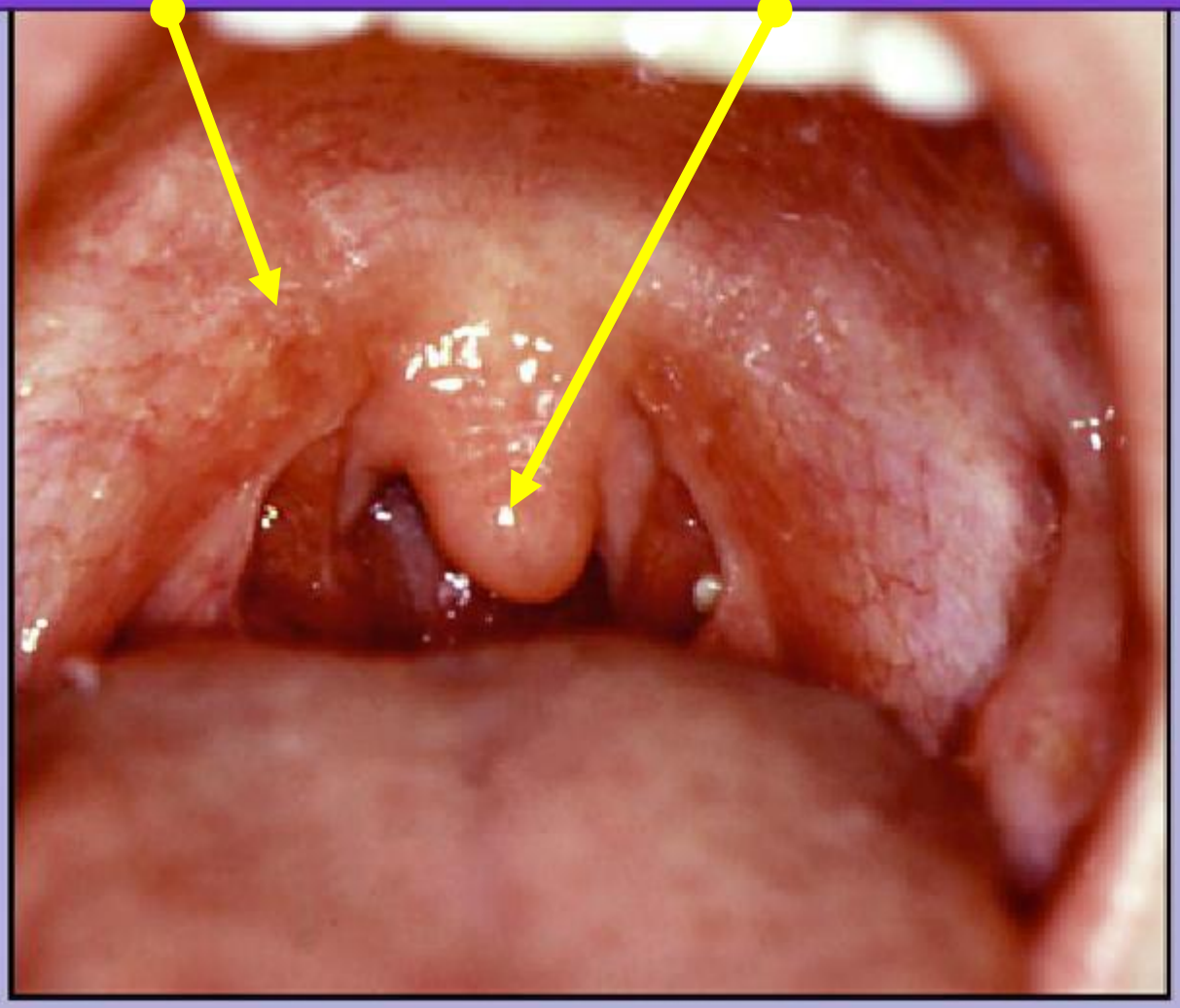

The uvula is the fleshy lobe hanging down from the back of the soft palate.

Common Oral Conditions

- Acquired
- Developmental
- Congenital

Acquired Oral Conditions

- Candidiasis
- Glossitis
- Primary Herpetic Gingivostomatitis
- Recurrent Aphthous Ulcer
- Discolored Teeth

Candidiasis

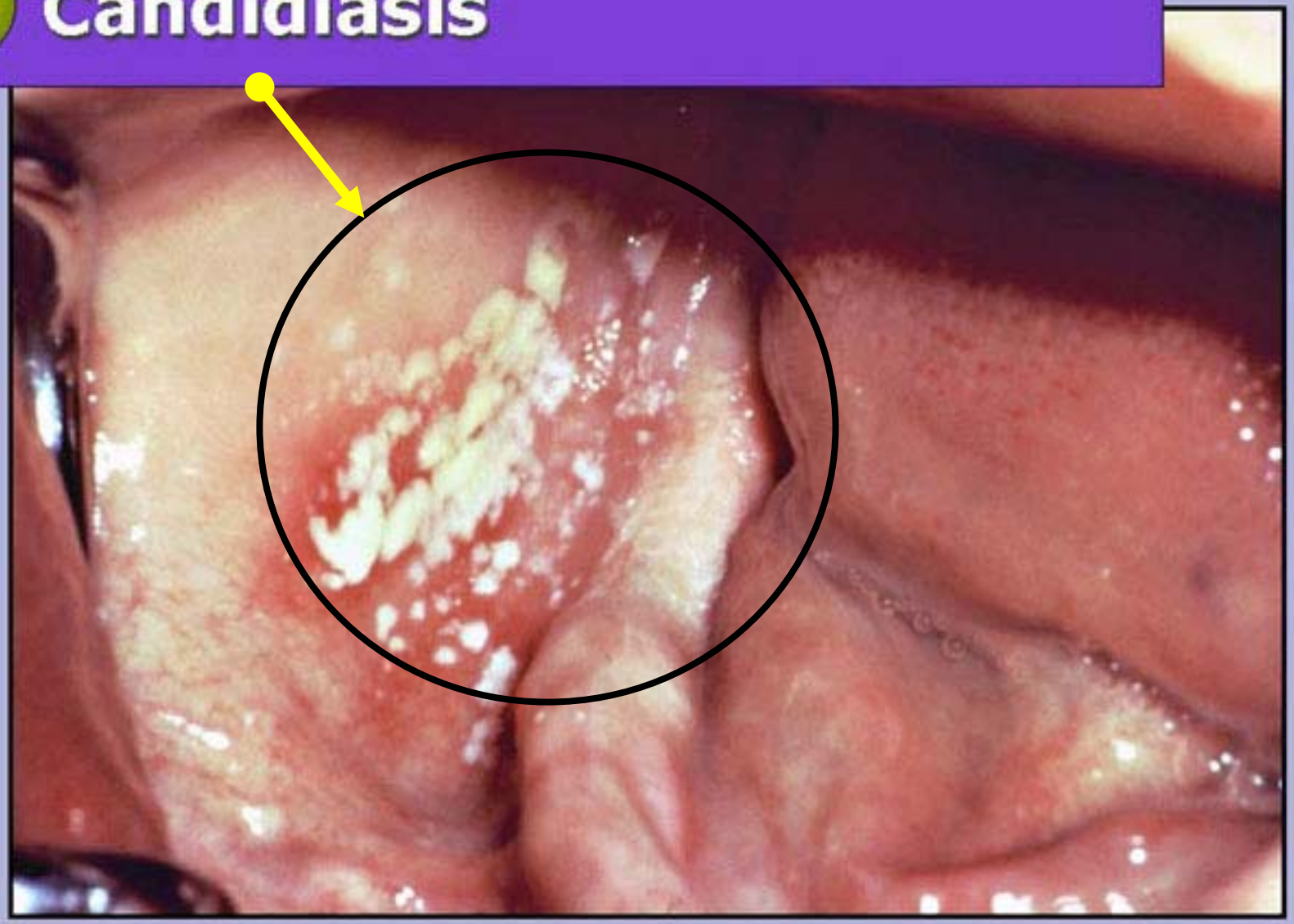

An infection in the mouth by the fungus, Candida Albicans, is known as thrush, and it is characterized by white patches on a red surface.

Candidiasis

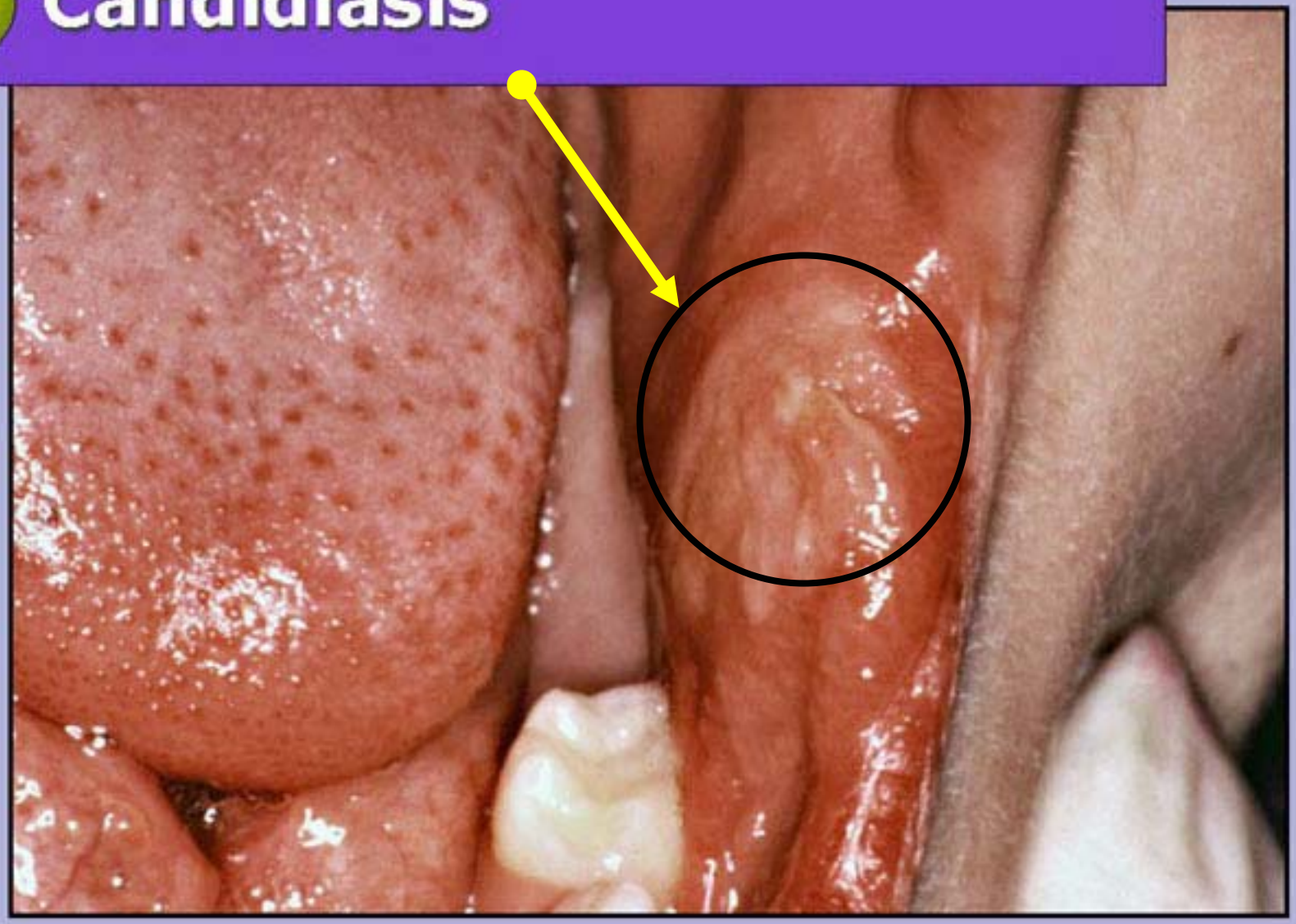

Glossitis

An inflammation of the tongue

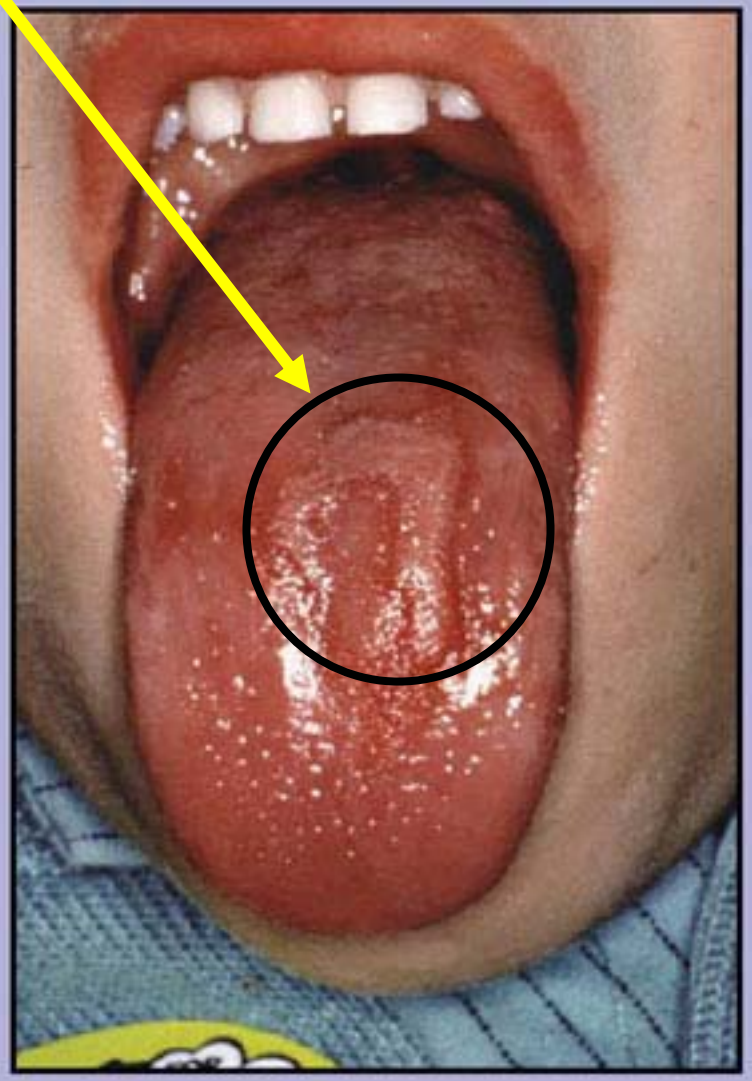

Primary Herpetic Gingivostomatitis

This is the initial outbreak of an infection with the virus, Herpes Simplex. In this picture painful sores can be observed on the lips and gums. The gums are very red and swollen.

Primary Herpetic Gingivostomatitis

Sores can also be inside the mouth on the tongue, floor of the mouth, throat and cheeks.

Primary Herpetic Gingivostomatitis (Symptoms)

- Fever
- Feeling run down and tired
- Enlarged lymph nodes in the neck
- Vesicles that progress to ulcers
- Occurs age 6 months to 6 years
- Spontaneous healing in 1 to 2 weeks
- Acute phase lasts 7 to 10 days

Primary Herpetic Gingivostomatitis

- Rest, Take medication for fever and pain
- Soothing mouthrinse
- Orabase®, or petroleum jelly, as a protective barrier
- Dehydration is a concern
- Patient is contagious
- Antibiotics and steroids contraindicated

Aphthous Ulcer

- Three Subtypes

Minor (most common)

- Generally located on the lining of the lips, cheeks, soft palate and floor of the mouth
- Tend to be small and shallow ulceration

Major

- Larger and deeper ulceration

Herpetiform

- More numerous and look like blisters

Aphthous Ulcer

Aphthous Ulcer

- Cause is unknown
- Treat to relieve symptoms
- Healing
  - Minor – 7 to 10 days, without scarring
  - Major – 2 to 4 weeks, may scar

Discolored Teeth

- Discolorations inside the tooth
  - Fluorosis – enamel color change and irregularities
  - Tetracycline – dark bands
- Discolorations on the tooth surface
  - Iron stain - accumulation of Iron from supplements

Fluorosis (Mild)

White flecking of the enamel in mild fluorosis

Fluorosis (Moderate)

Moderate and severe forms of fluorosis have changes in the enamel surface and color that are easier to see.

Tetracycline Stain

Mild

Tetracycline Stain

Moderate

Tetracycline Stain

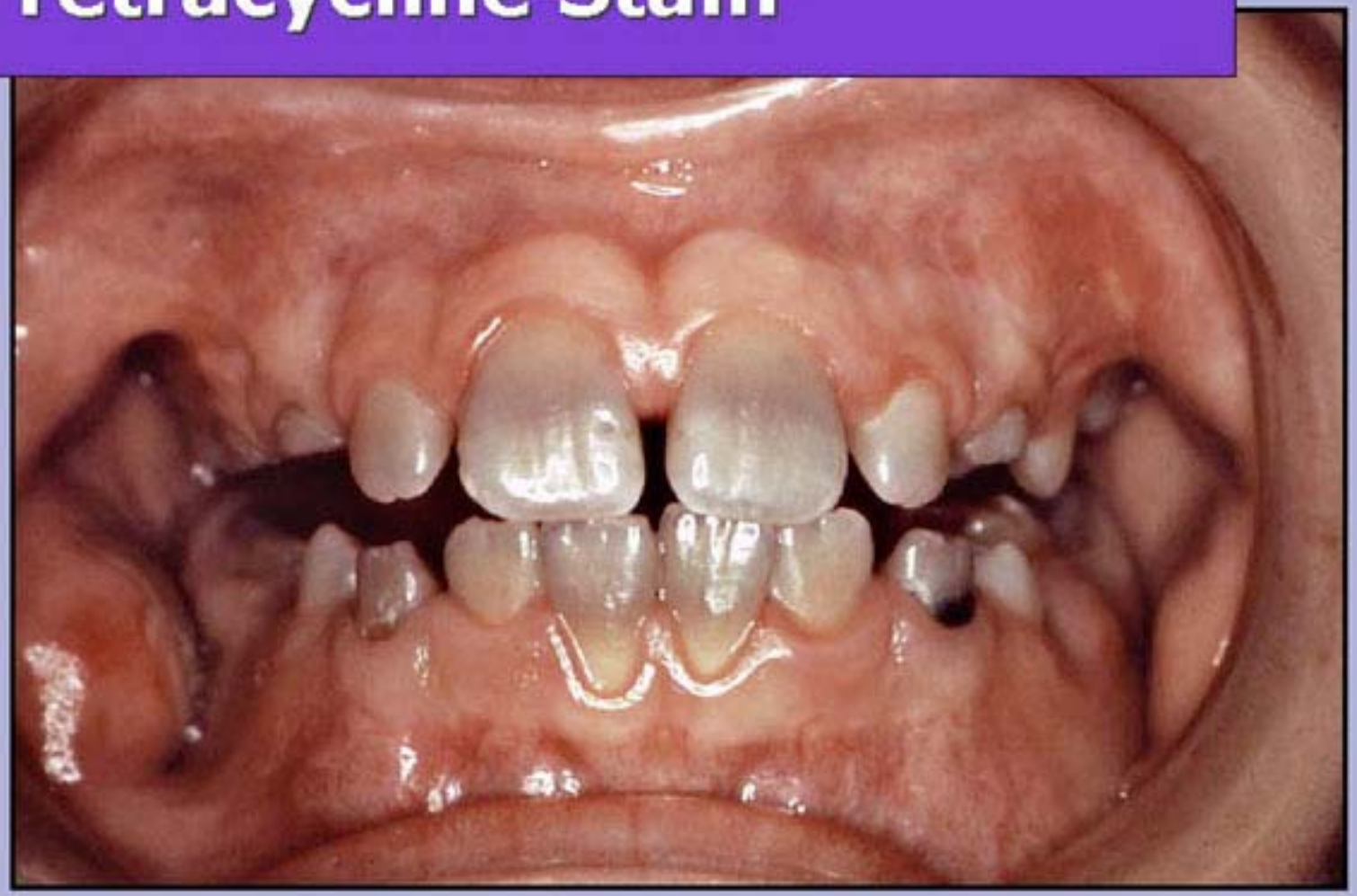

Severe

Tetracycline Stain

Severe

Stain from Iron Drops

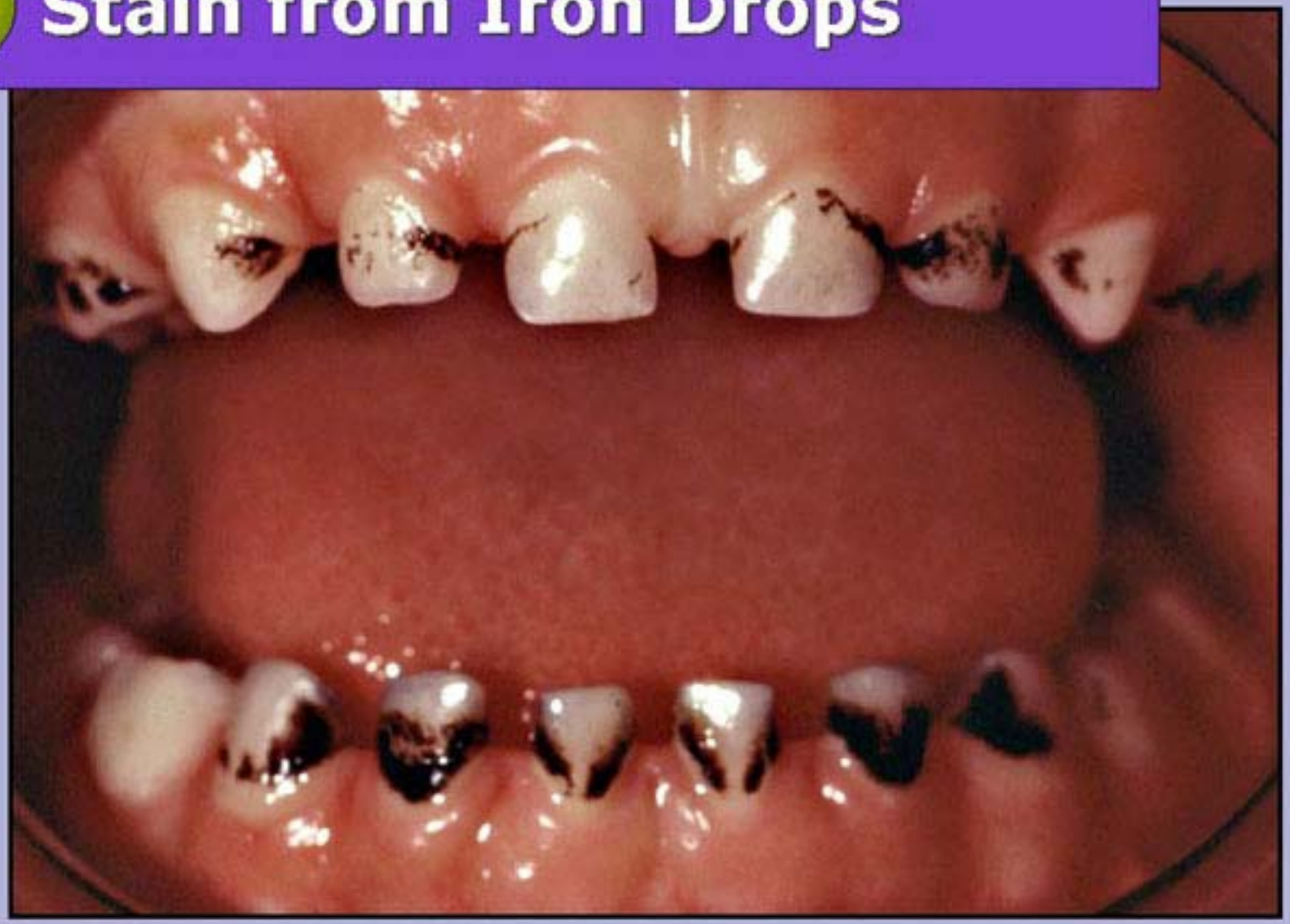

The dark brown on these teeth is from iron and can be removed.

Developmental Conditions

- Mucocele
- Ranula

Mucocele

Fluid trapped beneath a thin layer of mucous membrane

Ranula

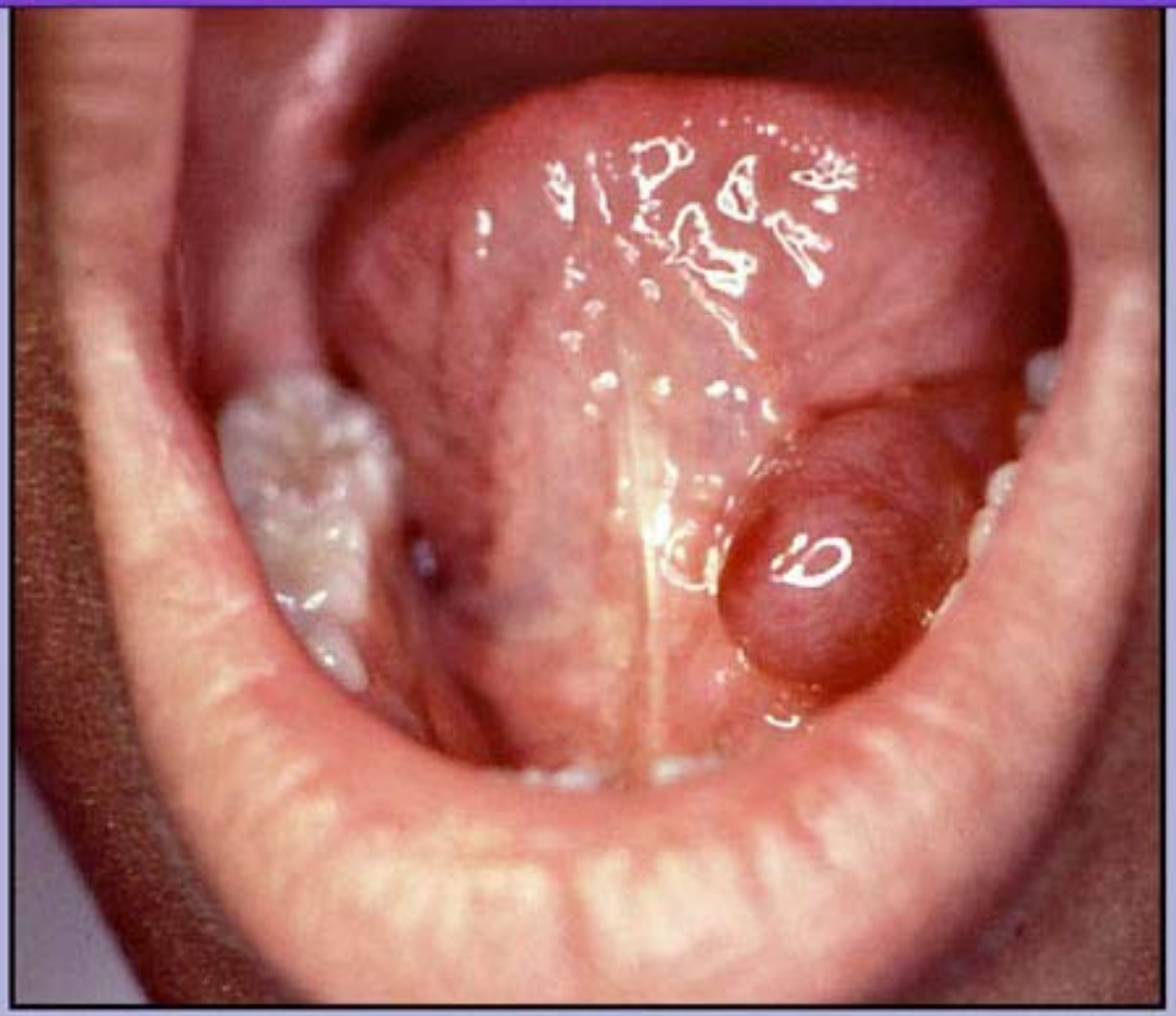

The same as a mucocele but located on the floor of the mouth

Congenital Oral Conditions

- Ankyloglossia
- Submucous Clefts
- Congenital Epulis of the Newborn
- Natal Teeth
- Hemangioma

Ankyloglossia

The lingual frenum is too short resulting in a tongue-tied condition

Congenital Epulis of the Newborn

- Benign lesion
- Present at birth
- Frequent in females in the anterior maxillary arch
- May cause feeding and respiratory problems
- Spontaneous regression or excisional biopsy
- Recurrence rare

Congenital Epulis of the Newborn

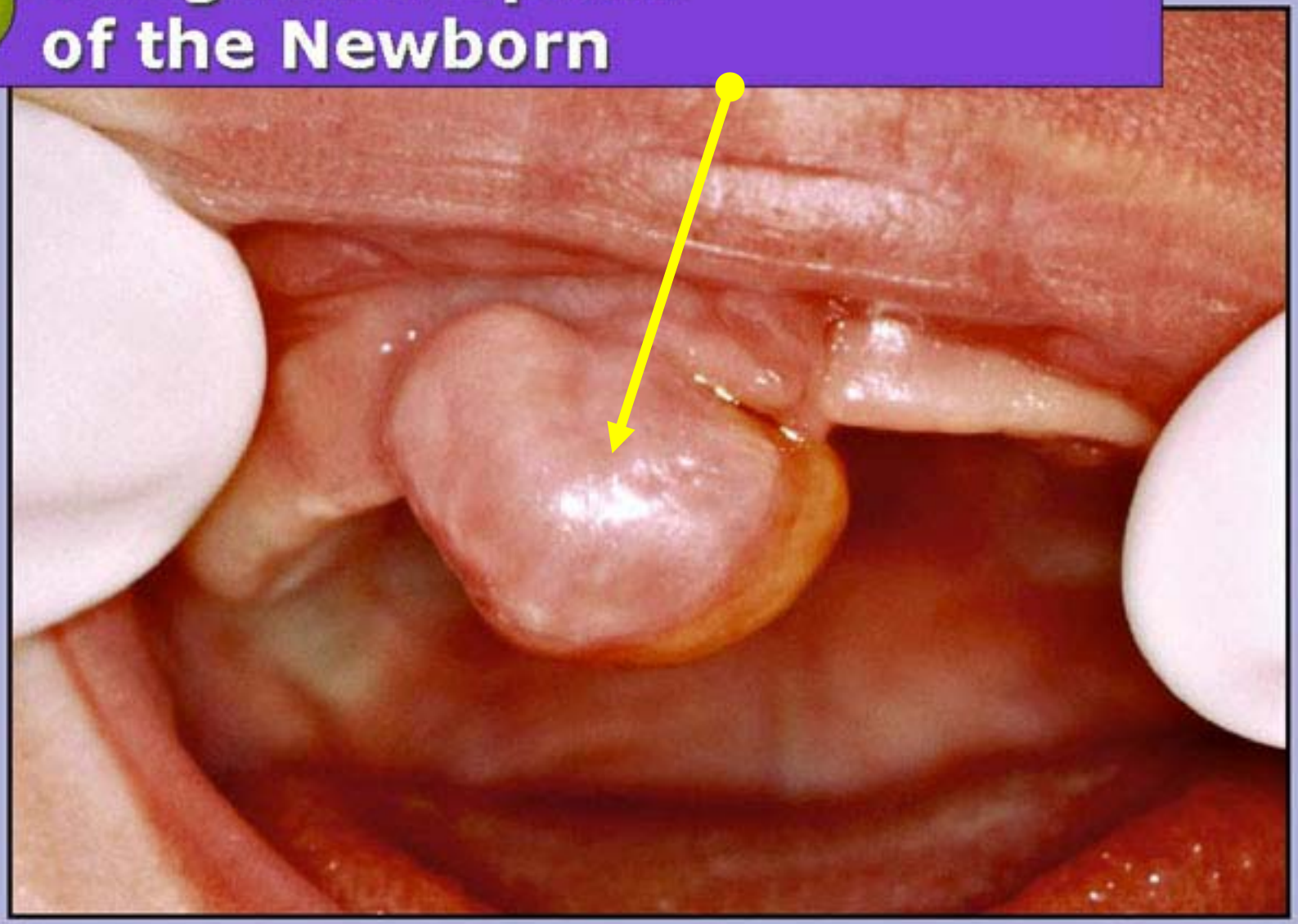

A tumor or abnormal enlargement of the gum tissue present at birth.

Natal Teeth

- Premature eruption of preliminary teeth
- Tooth should be retained unless mobile

Natal Teeth

Natal Teeth

Hemangioma

- Occurs within first year
- Female predilection
- Local or diffuse, red to blue color
- Flat or modular, compressible
- Commonly located on lips, tongue, or buccal mucosa
- Hemorrhage from trauma is common
- May require surgery or may heal spontaneously

Hemangioma

Eruption Patterns

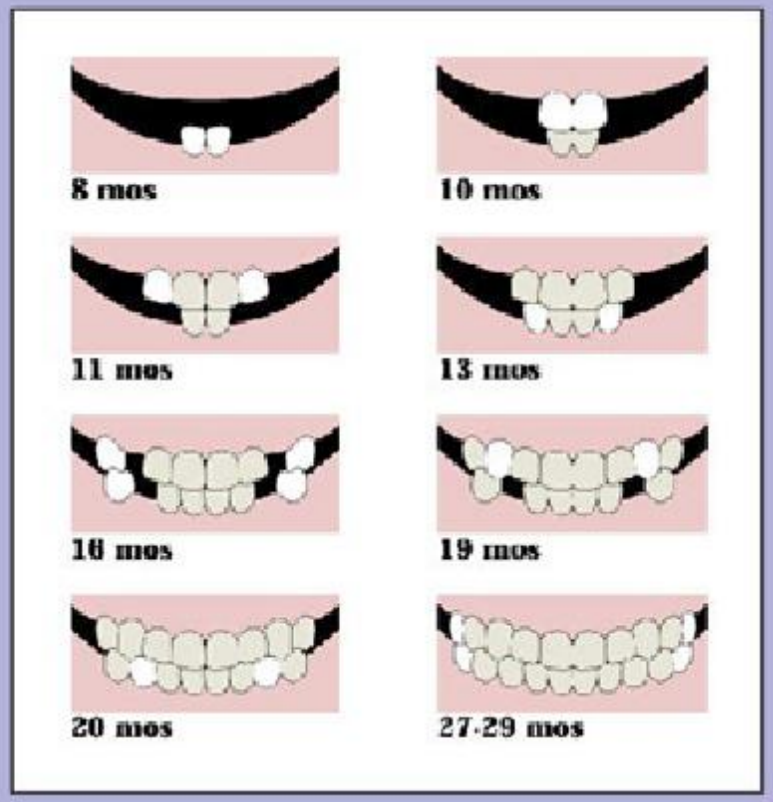

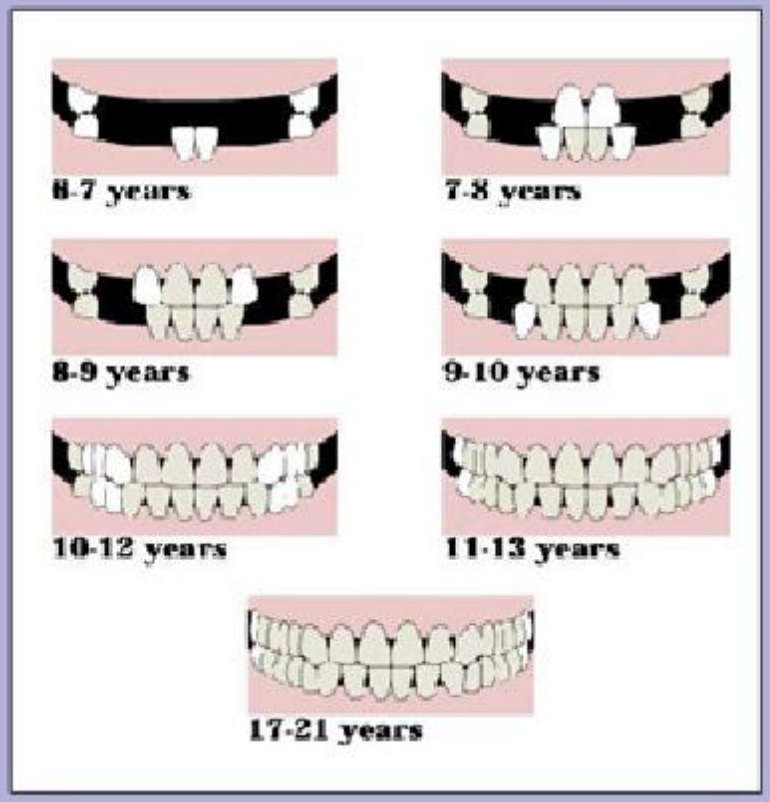

Approximate eruption times

Eruption Patterns

- Tooth formation begins 7 weeks in utero
- Mineralization begins at 4th month of fetal development
- Symmetrical eruption pattern
- Mandibular teeth erupt first
- Sequence is more important than timing

Eruption Patterns
Primary Teeth

- 6 months

  Primary mandibular central incisors
- 7 months

  Primary maxillary central incisors

Approximate Tooth Eruption Schedule =

"7 + 4" Guideline

7 Months =
First Primary Teeth Erupt

11 Months = 4 Erupted Primary Teeth

7 Months
+4

11 Months

0 Teeth
+4

4 Teeth

15 Months =
8 Erupted Primary Teeth

11 Months
+4

15 Months

4 Teeth
+4

8 Teeth

19 Months = 12 Erupted Primary Teeth

15 Months
+4

19 Months

8 Teeth
+4

12 Teeth

23 Months = 16 Erupted Primary Teeth

19 Months
+4

23 Months

12 Teeth
+4

16 Teeth

27 Months = 20 Erupted Primary Teeth

23 Months
+4

27 Months

16 Teeth
+4

20 Teeth

Eruption Pattern: Permanent Teeth

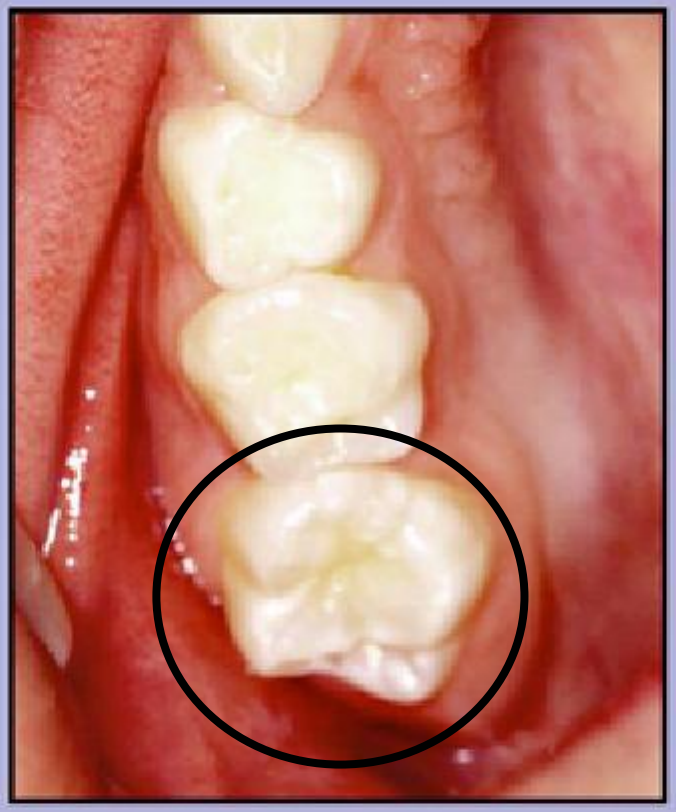

6-year molar

12-year molar

Eruption Pattern: Permanent Teeth

Anterior

Eruption Bulge

Teething Process

- Natural process
- Increased drooling
- Desire to bite or chew
- Mild pain
- No evidence of high fever, diarrhea, facial rash, or sleep problems

Dental Caries and Prevention

Dental Caries: Etiology

TOOTH

Age
Fluorides
Morphology
Nutrition
Trace Elements
Carbonate Level

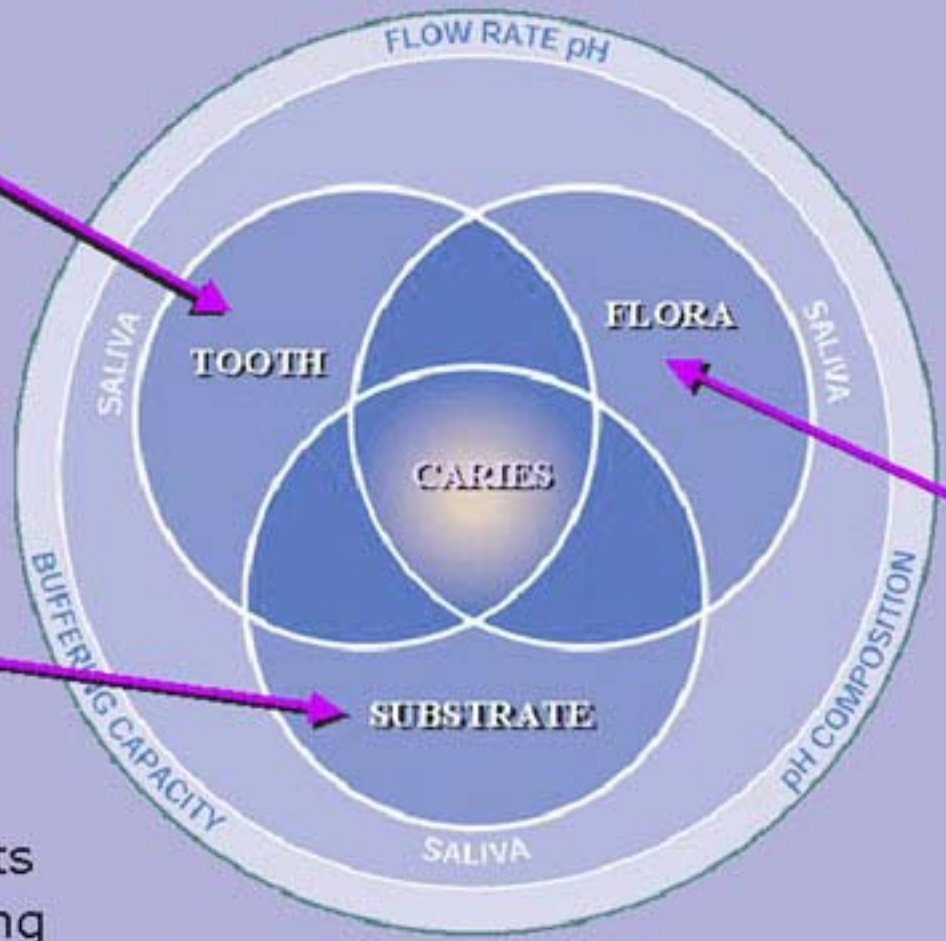

SUBSTRATE

Oral Clearance
Oral Hygiene
Salivary Stimulants
Frequency of Eating
Carbohydrate (type, concentration)

FLORA

Strep, Mutans
(Substrate)
Oral Hygiene
Flouride in Plaque

Dental Caries: Etiology

Caries (tooth decay or cavities)

- a disease that involves many factors
- the disease process is started by bacteria (*Streptococcus Mutans).*
- bacteria break down carbohydrates (sugar is a carbohydrate)
- acids are produced that cause minerals to be lost from the teeth
- mineral loss results in cavities

Three things must be present for tooth decay to occur:

- a tooth
- bacteria (flora)
- sugar (substrate)

Streptococcus mutans Transmission

The germs that cause tooth decay are transmitted from the mouth of the mother to the baby.

Patterns of Decay

- Early Childhood Caries
- Pit and Fissure Caries
- Smooth Surface Caries

Early Childhood Caries

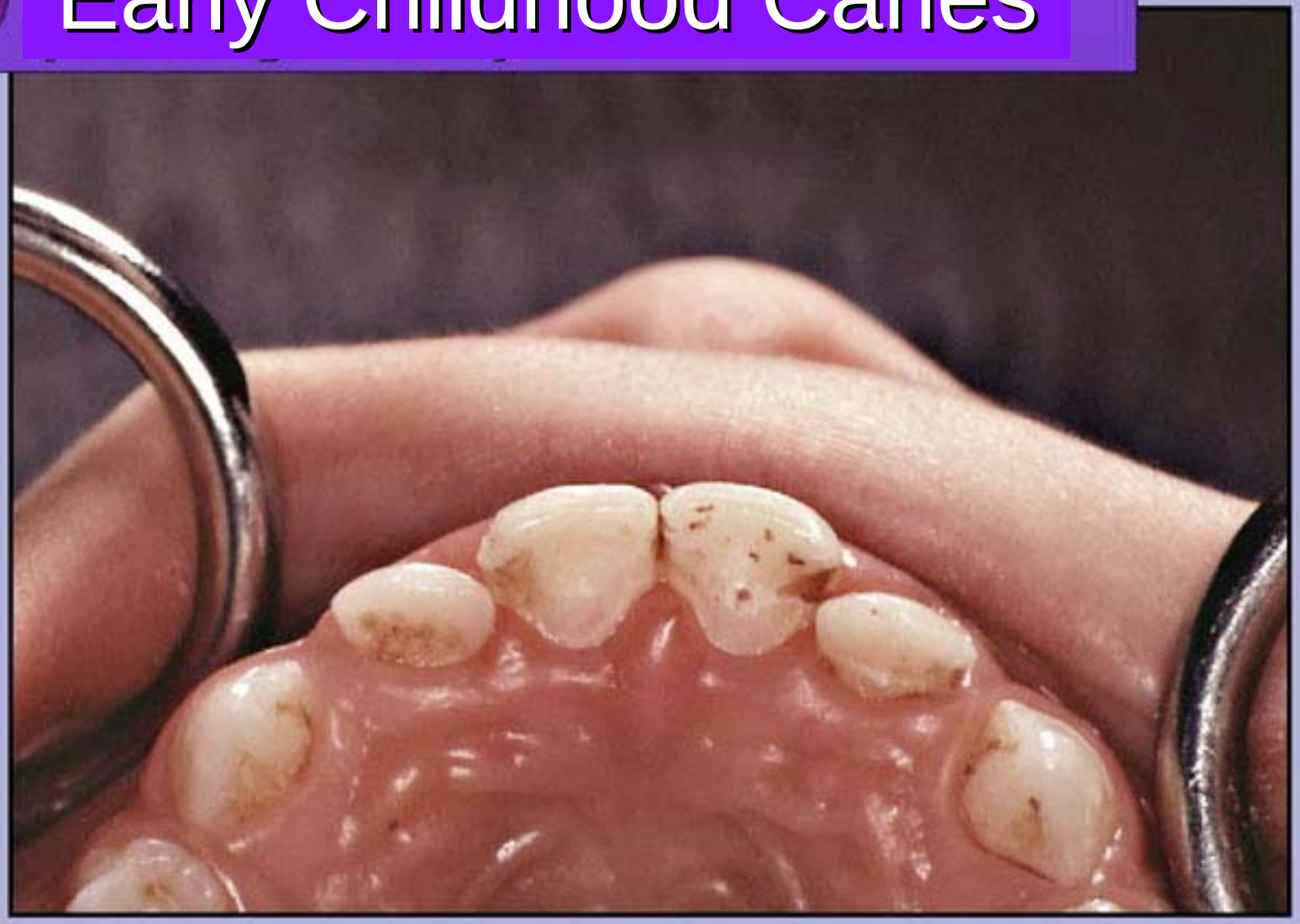

One or more decayed, missing, or filled primary teeth in a child less than 6 years old is ECC.

Early Childhood Caries

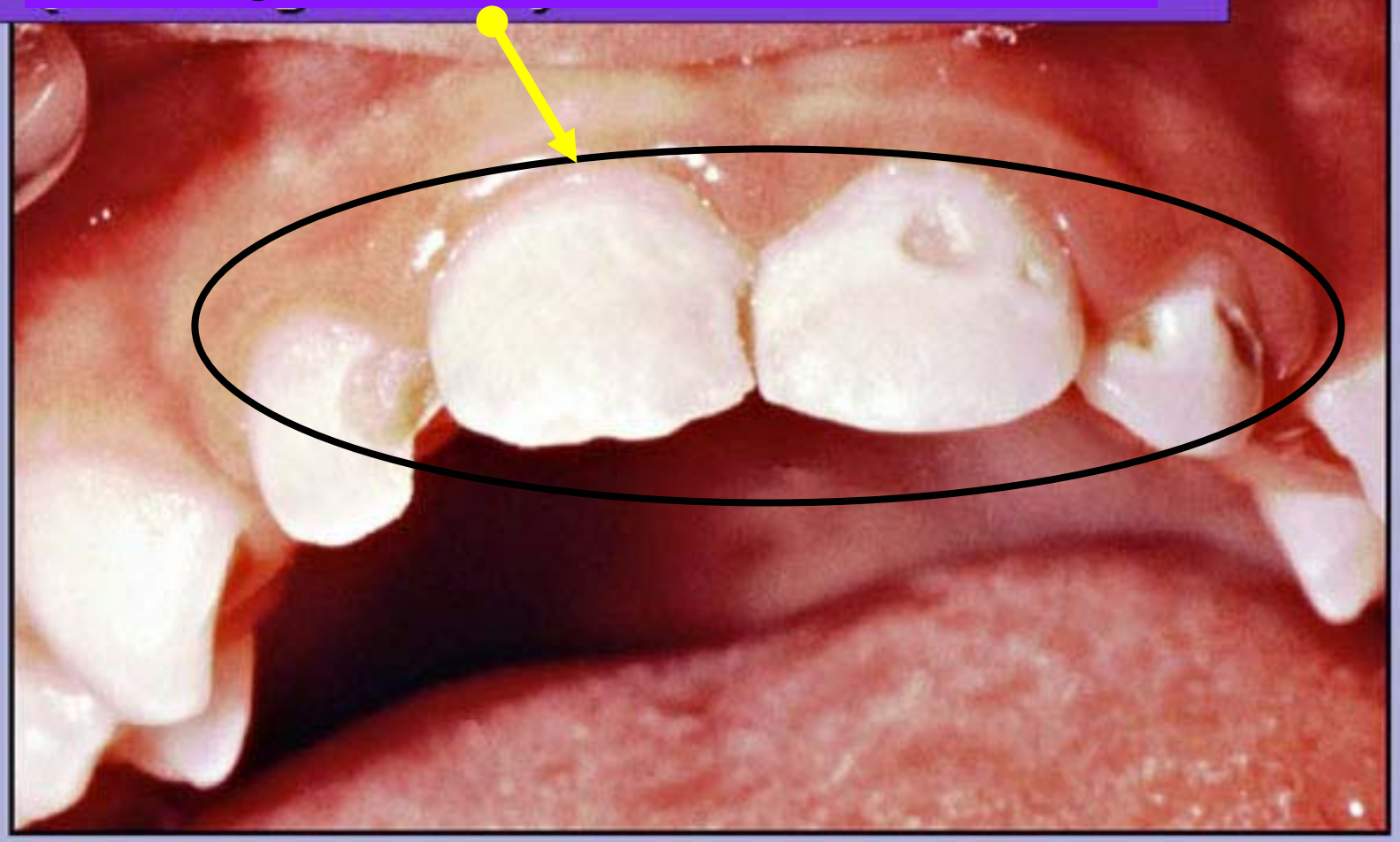

Mild

Early Childhood Caries

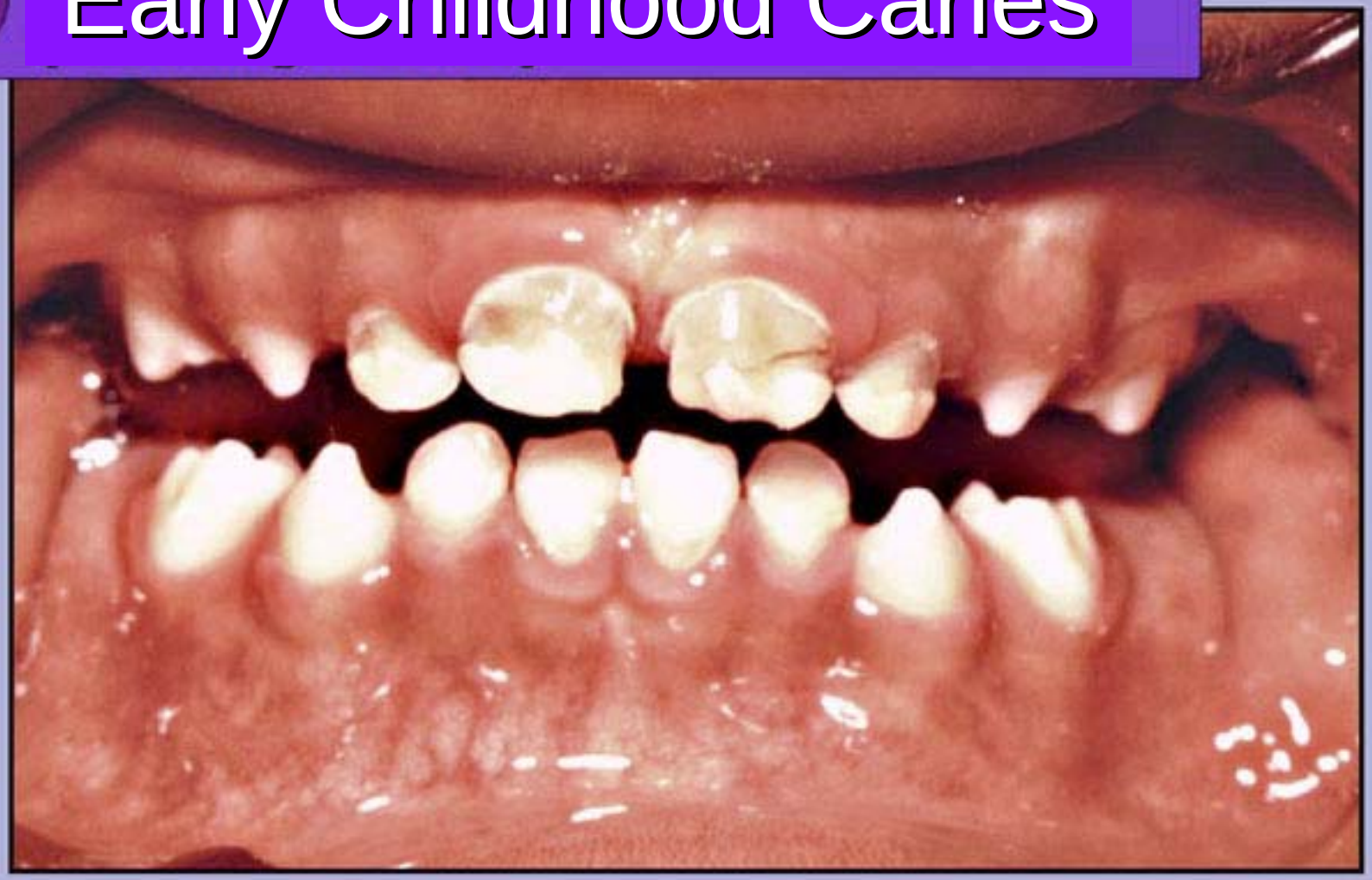

Moderate

Early Childhood Caries

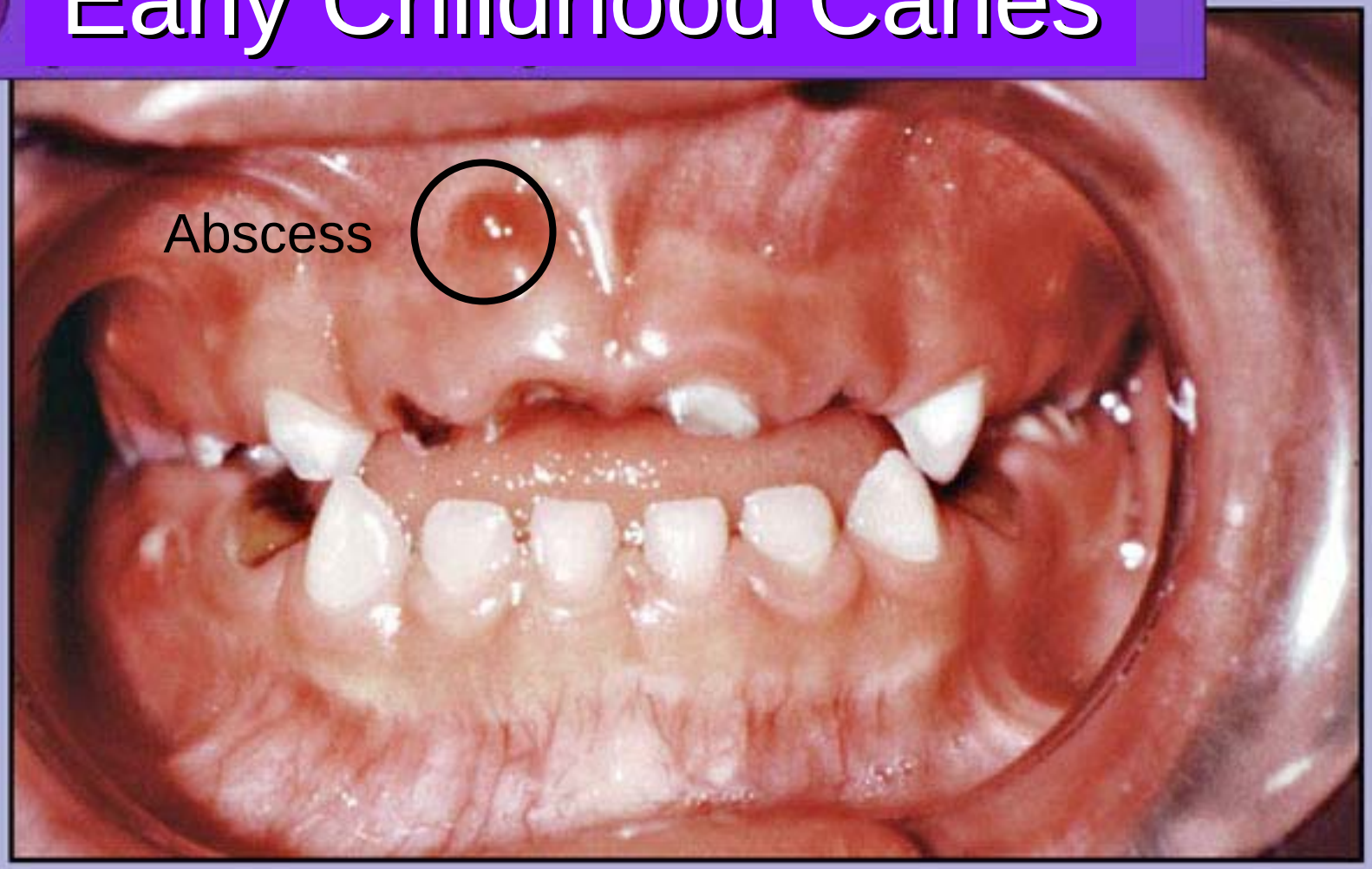

Severe

An abscess means the infection has spread to the inside of a tooth.

Pit and Fissure Caries

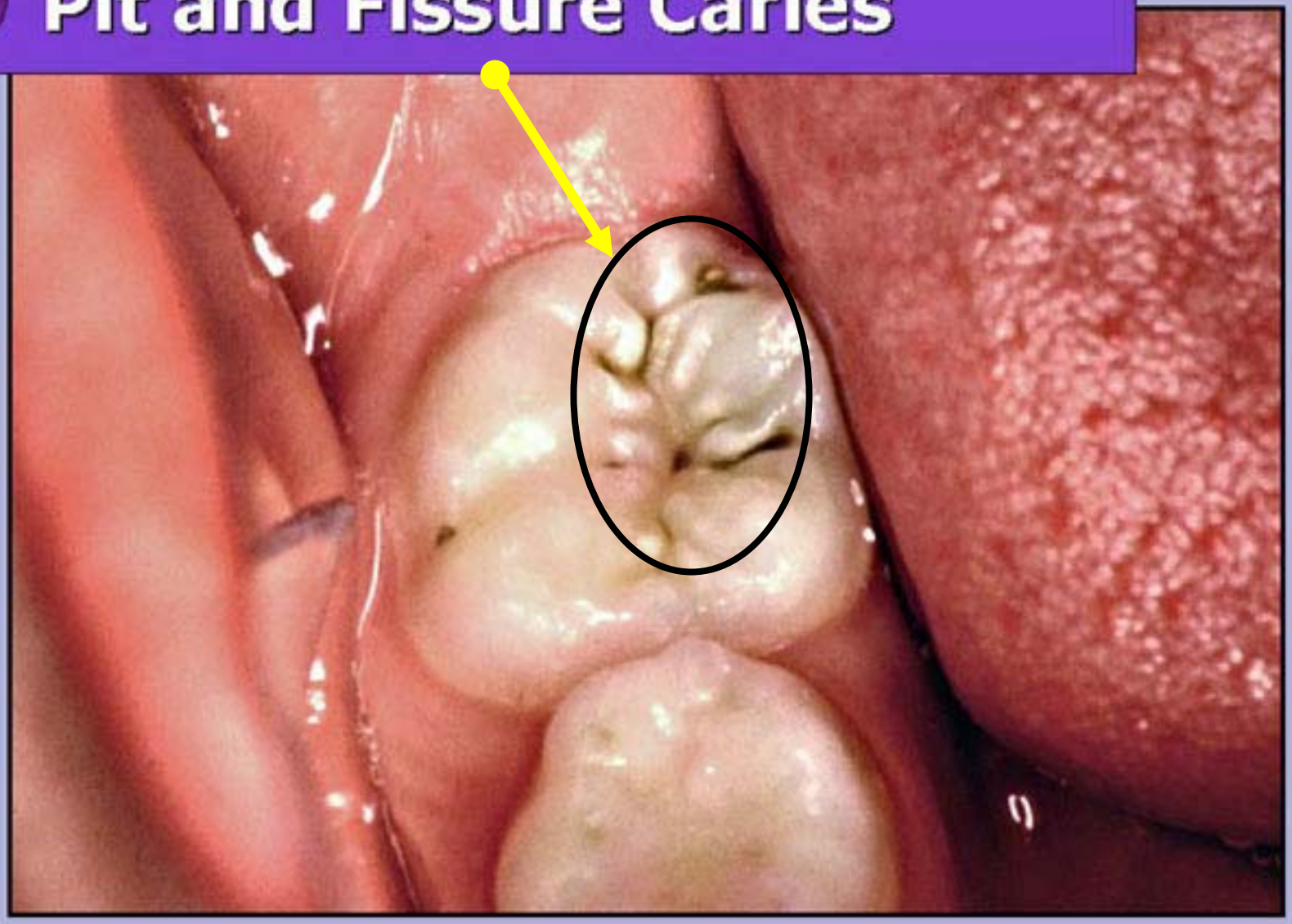

Decay in the crevices on the chewing surfaces of back teeth

Smooth Surface Caries

Facial cellulitis

Due to untreated dental abscess

Initial Dental Visit

- The American Academy of Pediatric Dentistry recommends a dental consultation shortly after the eruption of the first primary tooth.

Fluoride Supplements

- Prior to recommending supplementary fluoride, the fluoride content of the child's total water intake must be determined.

Fluoride reduces the risk of developing tooth decay.

ADA-Recommended Supplemental Fluoride Dosage Schedule

Age of Child	Water Fluoride Concentration (parts per million)		
	Less than 0.3	Between 0.3 - 0.6	Greater than 0.6
Birth to 6 Months	0	0	0
6 months to 3 years	0.25 mg liquid drops	0	0
3 to 6 years	0. 5 mg drops or tablet	0.25 mg	0
6 to 16 years	1.00 mg	0.5 mg	0

A dentist or physician must prescribe fluoride supplements.

Topical Fluoride

- 20% to 40% caries reduction
- Professionally applied
- Over-the-counter rinses
- Prescription rinses and gels
- Dentrifices

Over-the-counter rinses

- OTC rinses not recommended for children under 6 years of age
- Recommended for
  - Moderate to severe caries
  - Orthodontic patients
  - Patients with prosthodontic appliances

ADA-Approved Fluoridated Dentrifice

- Use with supervision under the age of 6
- Small pea-sized amount is needed



Nonnutritive Sucking Habits

- Normal neonatal development
- Rooting reflex
- Sucking reflex

Nonnutritive Sucking Habits

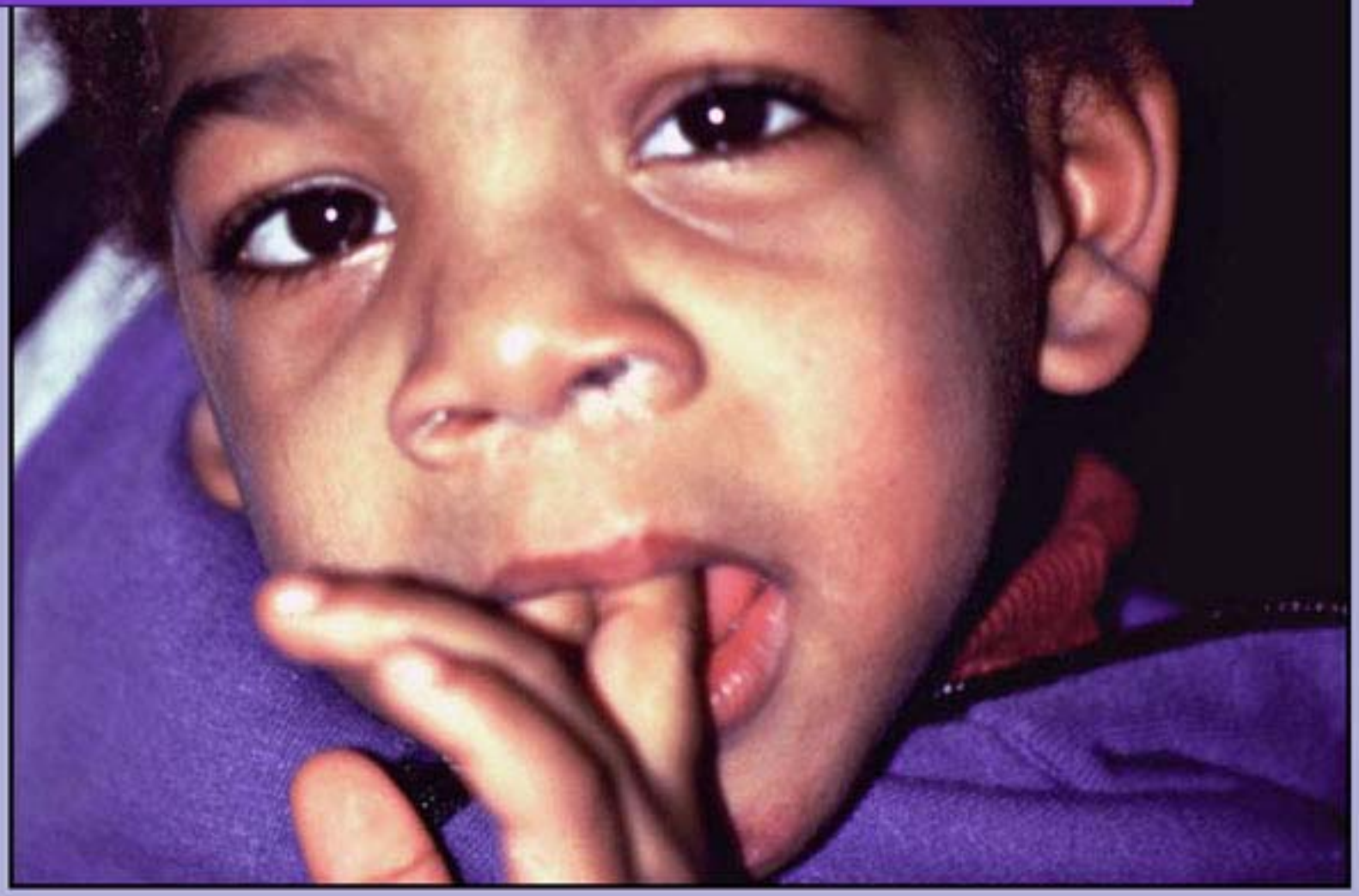

Nonnutritive Sucking Habits

- Spontaneous abandonment at 2 to 4 years of age
- May cause protrusion of upper anterior teeth
- Evaluate intensity, duration, and frequency of habit

Changes in dentition…

due to nonnutritive sucking habits

Changes in dentition…

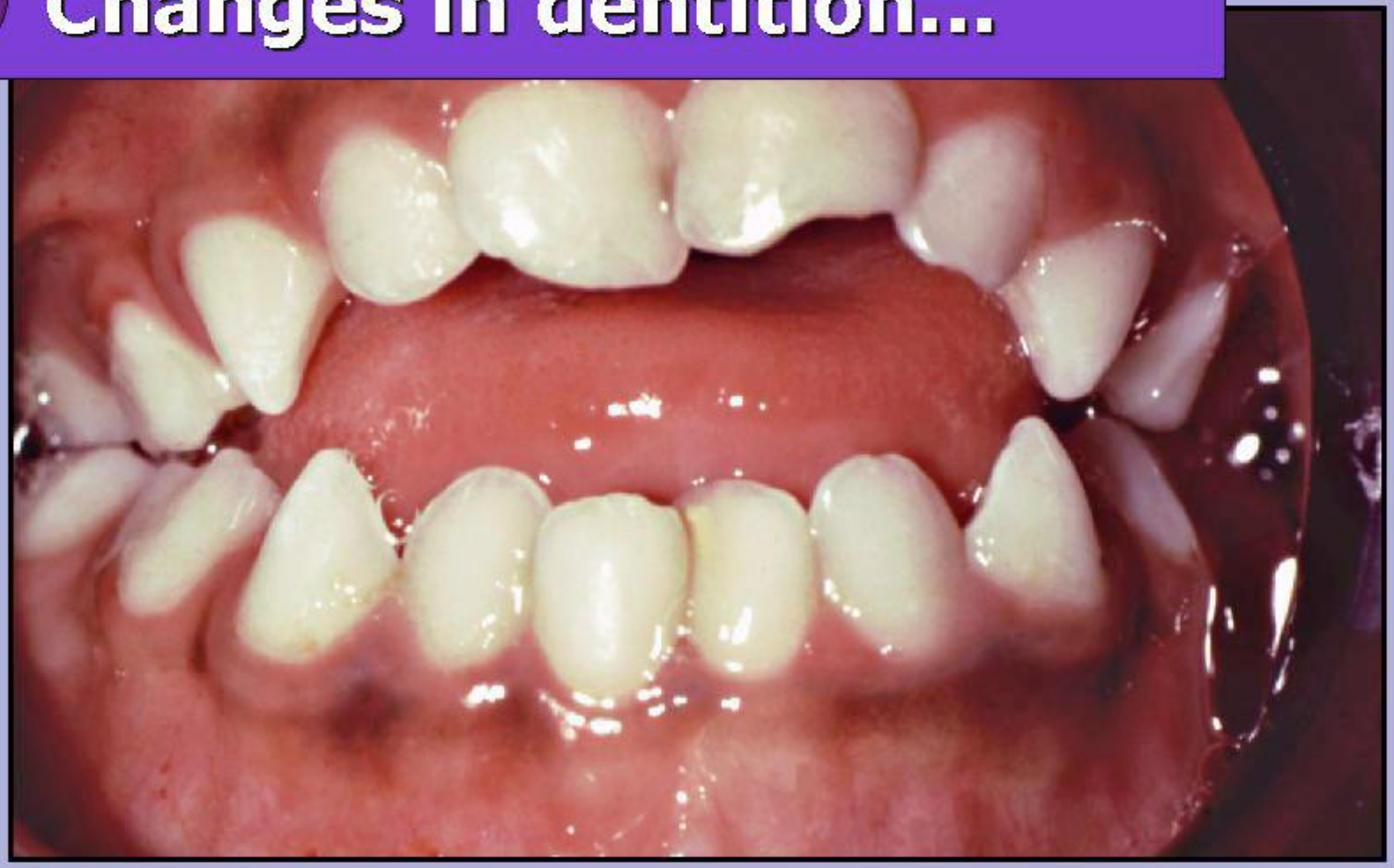

due to nonnutritive sucking habits

Nonnutritive Habit Intervention

- Habit normally ceases age 4 to 6 years
- Success depends on child's readiness

Pacifier Use

Pacifier Use and Safety

- Use only sturdy, one-piece, nontoxic, flexible pacifier
- Never attach around child's neck
- Discourage use of sweeteners
- Replace the pacifier when worn

Orofacial Trauma

- Injuries to primary and permanent dentition

Orofacial Injury Assessment

- Review health history
- Assess systemic/neurological effects
- Evaluate tetanus immunization
- Be alert to potential child abuse

Injury Classification

- Fracture
- Displacement
- Avulsion

Fractured Primary Tooth

Fractured Permanent Teeth

Intruded Permanent Teeth

Teeth are jammed into the gum

Extruded Permanent Teeth

Teeth that are pushed out of the gum tissue and bone

Avulsion Site

Knocked out (avulsed)

Avulsion Site

Avulsed Permanent Tooth

- Reimplant ASAP
- Do not scrub clean - rinse
- If unable to implant, transport to dental office in milk or saline
- Plan for root canal therapy

Soft Tissue Injuries

- Laceration - a wound produced by tearing
- Treatment

  Hemorrhage control

  Wound cleansing

  Suture as indicated

  Antibiotics for "through and through" lacerations

Laceration of Tongue

Frenum Laceration

Recent Electrical Burn

Prevention of Dental Trauma

Wear a mouthguard or mouth protector when playing sports to protect the teeth, lips, tongue, face and jaw.

Prevention of Dental Trauma

Pediatric Oral Health

Information in this program was adapted from a series on oral health for healthcare professionals by the American Academy of Pediatric Dentistry, and Proctor and Gamble Oral Health Products. The information has been revised to be useful to general audiences.